



# Dialogues in Pediatric Urology

An official publication of the Society for Pediatric Urology

Richard M. Ehrlich, M.D., Founding Editor / William J. Miller, Founding Publisher

Volume 34, Number 1  
December 2012

**Editor:** Elizabeth B. Yerkes, MD

**Associate Editors:** Earl Y. Cheng, MD

Martin A. Koyle, MD

**Editorial Board:**

Jeffrey Campbell, MD

Marc Cendron, MD

Yutaro Hayashi, MD

Antonio Macedo, Jr., MD

Lane S. Palmer, MD

John Park, MD

Serdar Tekgul, MD

**Managing Editor:** Lorraine M. O'Grady

## CONTRIBUTORS

**Daniela C. J. Sanchez**

**Hiep T. Nguyen MD**

**C.K. Yeung, MD, FRCS, FRACS, FACS**

**Daniel P. Casella, MD**

**Steven G. Docimo, MD**

**Armando J. Lorenzo, MD MSc FRCSC  
FAAP FACS**

**Pankaj Dangle, MCh**

**Mohan S. Gundeti MB MCh FEBU  
FRCS**

**Dr. Jorge A. Garcia Andrade**

**Marc Cendron, MD**

**Hiep Nguyen, MD**

**Aditya Bagrodia, MD**

**Patricio Gargollo, MD**

**Dr. J. Moldes**

**Dr. R. Vagni**

**Dr. E. Ormaechea**

**Dr. S. Callelo**

**Dr. F. de Badiola**

**Marcos Giannetti Machado, MD**

**Maria Marcela Bailez, MD**

**Estela Susana Cuenca, MD**

## Update and Controversies in Laparoscopic Paediatric Urology - Part III

### FROM THE GUEST EDITOR

**Pedro Jose-Lopez, MD and Francisco L. Reed, MD**  
**Hospital Exequiel González Cortes & Clínica Alemana, Santiago Chile**

Sadly, this is our last issue of this series "*Update and Controversies in Laparoscopic Paediatric Urology*". In our first issue we exposed the idea that to perform big reconstructive surgeries in minimally invasive paediatric urology we should learn to "cradle", then "take some steps", subsequently "walk" and at the end to "run".... and hopefully with some style. In this issue we should be able to learn how to "run with style".

The topics in this number will go through difficult surgeries that most of paediatric urology would doubt –not with no good reasons- to perform them with MIS. Difficult pathology like urine incontinence, bladder augmentation and DSD & Vaginoplasty are beautifully discussed by our expert, trying to take all the possible points of view, just to give you a broad description of the current status of each of those conditions.

Once again, the final decision to do one of these approaches or not is back to you, your team and which would be the best for your patient, but at least you have the opportunity to think about it and/or ...to have it in mind.

As Guest Editors, we would like to sincerely thank all our expert friends who had contributed to this series. Without their honest exposition of their techniques, their experience, their pitfalls and useful tips, this series would never come out to public light. THANK YOU very much. On the other hand, we are pretty sure that all the contributors would be more than happy to get in contact with you if there is any doubt or comments.

We also would like to truly thank Elizabeth and Tony, Dialogues Editors who trust us with this "mission"; it was really our honour and pleasure to work with you.

For last time, we would like to invite you to relax and enjoy the 3rd issue of the series "*Update and Controversies in Laparoscopic Paediatric Urology*", which hopefully will help us to "run with style."

### FROM THE EDITOR

**Elizabeth B. Yerkes, MD**

One of the best features of *Dialogues in Pediatric Urology* is in the name: an opportunity to capture dialogue about how we *really* do things. Published outcomes are lovely, but the nuts and bolts are often missing. *DPU* gives us the opportunity to share both data and observations and ideas. As stated by Francisca Yankovic back in Part II: "Sometimes we can learn more from our instincts and lively debate than from the written word."

I feel fortunate to be the one to read these contributions first, as I have already picked up a few tricks that will hopefully result in less gnashing of teeth during robotic reconstruction cases.

Please join me in commending Drs. Lopez and Reed on their enormous effort and success in bringing us all up to date with the real-life tips and tricks from leaders in MIS for Pediatric Urology. Well done!

**Society for Pediatric Urology**

500 Cummings Center, Suite 4550 ♦ Beverly, MA 01915 ♦ (978) 927-8330

[www.spuonline.org](http://www.spuonline.org)

# I. MINIMALLY INVASIVE TECHNIQUES FOR CORRECTION OF VESICoureTERAL REFLUX

## Transperitoneal Laparoscopic Surgery for Vesicoureteral Reflux

Daniela C. J. Sanchez and Hiep T. Nguyen MD

Department of Urology, Boston Children's Hospital, Boston, MA, USA

### Introduction

Vesicoureteral reflux (VUR) occurs in 1% to 2% of children and can be congenital or secondary to bladder outlet obstruction. Considered a polygenic condition, no specific genes for VUR have been identified, but the prevalence among siblings of children with VUR is 27% and 36% among children of parents with VUR. It is generally considered as a benign condition; however, when associated with other factors such as voiding dysfunction, it is a risk factor for ascending urinary infection (UTI) that can then lead to hypertension, renal scarring and renal insufficiency.<sup>1</sup>

Management of VUR is controversial. In general, to prevent UTI and renal injury, most patients are treated with antibiotic prophylaxis until reflux resolves or they need surgical intervention.<sup>1</sup> Low-grade reflux is likely to resolve spontaneously, while high-grade cases may require surgical intervention. Currently, the gold standard surgical approach is the open ureteral reimplantation, which has high durable effectiveness rates. Recent technological advancement has allowed for a less invasive approach in the surgical treatment of VUR. With enhanced dexterity and outstanding visualization, robotic assistance has made the laparoscopic repair of VUR less difficult. Consequently, robotic assisted laparoscopic ureteral reimplant is gaining popularity for the potential advantages of reduced pain and shorter hospital stay.<sup>2</sup>

### The Laparoscopic Approach

Laparoscopic antireflux surgery was first reported in 1994, describing the use of the extravesical Lich-Gregoir technique through a transperitoneal approach.<sup>3</sup> Even though the procedure was successful, the authors report technical difficulties and longer operating time. Lakshmanan and Fung reported in 47 children (71 ureters) on a modified and refined version of this laparoscopic technique that minimized the pelvic tissue dissection, preserved the essence of open surgery, and had no incidence of persistent reflux or obstruction.<sup>4</sup> Although overall success rates were comparable to open techniques, this procedure was found to be technically challenging. The authors also highlighted the need of careful patient selection since the narrow pelvis of children younger than 4 years old and ureters requiring tapering may pose additional technical difficulties.

### The Robotic Approach

Despite the encouraging success of the laparoscopic approach in correcting VUR, technical demands of the procedure prevented its popularity. Recent advances in robotic technology provided a potential solution. Robotic assisted surgery (RAS) with its stereoscopic three-dimensional vision, increased instrument maneuverability, shorter learning curve for skill-intensive procedure, and tremor-filtered instrument control with movement scaling is useful in a laparoscopic procedure that is technically challenging.<sup>5</sup> With RAS, the advantages of laparoscopy (such as reduced pain, morbidity and hospital stay) are combined with those of robotic assistance, namely precision and ease of use. However, there are significant disadvantages with RAS, in-

cluding the added equipment cost to the host institution, the increased operative times required, and the required support from the ancillary operative staff. Interestingly, these limitations are the same as those encountered with laparoscopic surgery early in its development.<sup>6</sup>

In 2004, Peters was the first to describe initial experience with robotic assisted laparoscopic ureteral reimplantation (RALUR) in pediatric population.<sup>7</sup> The transperitoneal Lich-Gregoir procedure was performed in 17 children and a transvesical ureteral reimplantation, using the Cohen cross-trigonal technique, in 3 patients. The mean operative time ranged from 2 to 3.5 hours. Correction of reflux was achieved in 89% of refluxing units and the postoperative complication rate was 12% (bladder leak in 2 cases and transient obstruction in 1). In a subsequent study, Casale et al. demonstrated that bilateral extravesical ureteral reimplantation can be safely performed with transperitoneal RAS.<sup>8</sup> In 41 children the success rate was 97.6% with a range in operative time from 1.4 to 3.19 hours. The authors speculated that RALUR allows for improved visualization and as a result, preservation of the pelvic plexus in order decrease the incidence of postoperative urinary retention and bladder dysfunction. In another study, Lendvay observed a 12.5% complication rate (one unilateral ureteral leak demanding temporary bladder catheterization and one transient postoperative ureteral edema after bilateral reimplantation leading to azotemia requiring stenting). All complications and failures were seen in children with a history of pre-existing elimination syndrome.<sup>6</sup>

Subsequent studies regarding bilateral nerve-sparing extravesical RALUR demonstrated similar success rates. Kasturi et al and Smith et al reported respectively 99.3% (in 150 patients) and 96% (in 25 children) success rate.<sup>9, 10</sup> Smith et al reported that 64% of the children who underwent extravesical RALUR were discharged to home on POD#1, compared to only 4% of the open intravesical group, and that morphine equivalent analgesia requirements were significantly reduced in the robotic group. In a more direct comparison, Marchini et al. evaluated children who underwent extravesical RALUR and open extravesical ureteral reimplant.<sup>2</sup> With a standardized pain management protocol, the authors observed no difference in pain, narcotic requirements, length of hospitalization or success rate between the two groups. However, they did note that many of the patients in the robotic group had bilateral reflux and hence, would have required an open intravesical surgery if the robotic option was not available. In their study, the morbidity of the open intravesical surgery was significantly higher than that of both open and robotic extravesical ureteral reimplantation.

### When is the Transperitoneal Laparoscopic/ Robotic (LR) Approach for Antireflux Surgery Advantageous?

Based on the current literature, the LR approach for antireflux surgery has similar success rate to that of open surgery and the results are durable. The operative time and complications (such as obstruction and bladder dysfunction) are slightly higher with this approach. In our

*(continued on next page)*

## Transperitoneal Laparoscopic Surgery (continued from previous page)

opinion, the potential for reduced morbidity (in terms of pain, narcotic requirement, length of stay and recovery time) is likely to be greater with the LR extravesical approach compared to open intravesical surgery. Consequently, there are specific cases in which this approach would be more advantageous. Older children and young adults with VUR who require antireflux surgery could potentially have a faster and easier recovery with the LR approach compared to the open surgery, particularly in those with bilateral reflux. Instead of requiring a bilateral intravesical surgery, a LR extravesical approach would be less morbid. In addition, as the child gets older, the bladder and ureters descend deeper in the pelvis, making open surgery more difficult. With the LR approach, visualization and access to the deep pelvis is much easier.

When comparing the laparoscopic to the robotic approach, RALUR is technically less demanding, as evident by its popularity over the conventional laparoscopic approach. In our experience of over 200 cases with an overall success rate of 96%, the operative time is shorter with RALUR (approximately 2 hours for unilateral cases and 2.5 hours for bilateral cases), though this is likely to depend on the individual surgeon's familiarity and comfort with laparoscopy and robotic surgery. However, the cost of the RAS is the most significant difference between these two approaches. Equipment (console, instruments and disposables) costs for RAS contributes greatly to the overall cost of the procedure. Nevertheless, with further technological advance and competition, these costs are likely to decrease in the future, making RAS more affordable.

In conclusion, not all patients who require surgical intervention for VUR would benefit from the LR approach. With careful and thoughtful patient selection, some patients will benefit from the advantages of the LR approach. Consequently, the LR approach should be a part of a pediatric urologist's armamentarium for the treatment of VUR.

### References

1. Routh, J.C., et al., *Vesicoureteral Reflux: Current Trends in Diagnosis, Screening, and Treatment*. *Eur Urol*.
2. Marchini, G.S., et al., *Robotic assisted laparoscopic ureteral reimplantation in children: case matched comparative study with open surgical approach*. *J Urol*. 185(5): p. 1870-5.
3. Ehrlich, R.M., A. Gershman, and G. Fuchs, *Laparoscopic vesicoureteroplasty in children: initial case reports*. *Urology*, 1994, 43(2): p. 255-61.
4. Lakshmanan, Y. and L.C. Fung, *Laparoscopic extravesicular ureteral reimplantation for vesicoureteral reflux: recent technical advances*. *J Endourol*, 2000, 14(7): p. 589-93; discussion 593-4.
5. Hayn, M.H., et al., *Minimally invasive treatment of vesicoureteral reflux*. *Urol Clin North Am*, 2008, 35(3): p. 477-88, ix.
6. Lendvay, T., *Robotic-assisted laparoscopic management of vesicoureteral reflux*. *Adv Urol*, 2008: p. 732942.
7. Peters, C.A., *Robotically assisted surgery in pediatric urology*. *Urol Clin North Am*, 2004, 31(4): p. 743-52.
8. Casale, P., R.P. Patel, and T.F. Kolon, *Nerve sparing robotic extravesical ureteral reimplantation*. *J Urol*, 2008, 179(5): p. 1987-9; discussion 1990.
9. Kasturi, S., et al., *Prospective Long-term Analysis of Nerve-sparing Extravesical Robotic-assisted Laparoscopic Ureteral Reimplantation*. *Urology*, 79(3): p. 680-3.
10. Smith, R.P., J.L. Oliver, and C.A. Peters, *Pediatric robotic extravesical ureteral reimplantation: comparison with open surgery*. *J Urol*. 185(5): p. 1876-81.

## Pneumovesicoscopic Surgery for Vesicoureteral Reflux

C.K. Yeung, MD, FRCS, FRACS, FACS

Department of Surgery, Chinese University of Hong Kong, Hong Kong

### Introduction

The intravesical technique of cross-trigonal ureteral reimplantation, as first described by Cohen and Politano-Leadbetter, has been a very reliable and time-tested procedure with very good and consistent results. Using the Cohen technique, McCool et al reported a 96% successful reflux resolution rate.<sup>1</sup> However, as the technique involves a sizable lower abdominal incision and forced retraction of the bladder, it necessitates post-operative urinary diversion with urethral and/or suprapubic catheterization. This together with the open bladder retraction often results in a high incidence of severe bladder spasms, hence an increased need for additional analgesics and antimuscarinic medications and usually a prolonged hospital stay.<sup>2</sup>

Different minimally invasive surgical techniques are now available for the management of vesicoureteral reflux (VUR). These include cystoscopic subureteric injection of various types of bulking agents, e.g. polytetrafluoroethylene (Teflon), collagen, dextranomer / hyaluronic acid co-polymer (Deflux), etc.; endoscopic ureteral advancement and trigonoplasty; and endoscopic ureteric reimplantation through a transperitoneal extravesical approach.<sup>3-7</sup> Currently, laparoscopic ureteric reimplantation for VUR utilizing the Lich-Gregoir technique can be performed in children through a transperitoneal extravesical approach. However, this approach necessitates transgression of the peritoneal cavity and can be technically difficult in the small pelvis of a young child. Furthermore, in cases with bilateral reflux requiring bilateral laparoscopic extravesical ureteric reimplantation, there is a significant concern for post-operative urinary retention and voiding dysfunctions.<sup>8</sup>

The concept of endoscopic ureteral reimplantation for treatment of VUR using an intravesical route under carbon dioxide (CO<sub>2</sub>) bladder insufflation, or *pneumovesicum*, is soundly based on several well-established facts. Firstly, the bladder is a natural body cavity that can be easily distended by gas insufflation, and cystometry using CO<sub>2</sub> bladder distension has been a long established investigative technique. Secondly, the Cohen cross-trigonal ureteral reimplantation has been most reliable and time-tested, and has indeed remained the standard anti-reflux surgical procedure in most pediatric urology institutes over the last few decades. Thirdly, from a pilot animal model using piglets, we have found that it is physiologically very safe to insufflate the bladder with CO<sub>2</sub> up to 15 mm Hg pressure, with no significant alteration in renal blood flow and glomerular filtration rates. Furthermore, the transitional urothelial lining of the bladder and the upper urinary tract does not normally absorb CO<sub>2</sub>, and hence there is no problem of systemic CO<sub>2</sub> absorption and hypercapnia. During the time of pneumovesicoscopic surgery, our experience shows that bladder insufflation to only around 10-12 mm Hg pressure is usually more than adequate to achieve a large working space to allow various intravesical procedures conducted endoscopically using standard laparoscopic instruments.<sup>9</sup> This includes a Cohen type of cross-trigonal ureteric reimplantation as well as other more complex intravesical reconstructive procedures, e.g. tailoring ureteroplasty for megaureters, diverticulectomy, excision of large ectopic ureteroceles, as well as bladder base and bladder neck reconstructions.

(continued on next page)

## Pneumovesicoscopic Surgery *(continued from previous page)*

We herein describe our technique of vesicoscopic cross-trigonal ureteric reimplantation under CO<sub>2</sub> insufflation of the bladder, or *pneumovesicum*, in the treatment of vesicoureteral reflux in infants and children, and we review our experience.

### Surgical Technique

The patient is positioned supine with the legs separated apart so that the surgeon can gain access to the urethral orifice for cystoscopy and bladder catheterization intra-operatively. For small infants the surgeon stands and operates over the patient's head, whereas for older children the surgeon usually stands on the patient's left side. The video monitor was placed between the patient's legs at the end of the table.

The endoscopic procedure is preceded by transurethral cystoscopy to allow placement of the first camera port under cystoscopic guidance. The bladder is first distended with saline, and a no.1 monofilament traction suture and is passed percutaneously at the bladder dome under cystoscopic vision, through both the abdominal and bladder walls. This helps to keep the bladder wall from falling away when the first camera port site incision is made and during insertion of the cannula. Under cystoscopic vision a small stab incision is made percutaneously over the bladder dome for the insertion of the first camera port. A 3-0 monofilament suture loop is now introduced into the bladder on one side of the stab incision via a 16G needle, then another 3-0 monofilament suture is then introduced on the other side of the stab incision and passed through the suture loop. Retrieval of the suture loop back to outside will bring the second suture out. This will form a hitching U-stitch that traverses the stab incision over the bladder dome where the camera port will then be inserted. Tightening of this hitching U-stitch over a short piece of rubber tubing placed just outside the abdominal wall will serve the following purposes: (i) securing the port to both the abdominal and bladder walls thus avoiding port dislodgement; (ii) prevent gas leakage into the extravascular space during subsequent CO<sub>2</sub> bladder insufflation; and (iii) the same hitching stitch can be used to close the port sites at completion of the procedure.

A 5-mm Step port (Tyco Inc, USA) is then inserted under cystoscopic vision through the stab incision over the bladder dome, and secured in position with the hitching U-stitch. A urethral catheter is then inserted to drain the bladder and carbon dioxide insufflation to 10-12 mm Hg pressure is started. The urethral catheter is used to occlude the internal urethral meatus to secure CO<sub>2</sub> pneumovesicum, and it can also serve as an additional suction irrigation device during subsequent dissection and ureteric reimplantation. A 5-mm 30-degree scope is used to provide intravesical vision. Two more 3-5 mm working ports are then inserted on either side along the bikini line on the lateral wall of the bladder. A short segment of a 4-6 Fr catheter is then inserted into the respective ureter, as a stent to facilitate subsequent ureteral mobilization and dissection, and secured with a 4-0 monofilament suture. Intravesical mobilization of the ureter, dissection of submucosal tunnel and a Cohen type of ureteral reimplantation is then performed un-

der endoscopic guidance, in a similar manner to the open procedure. Ureteroneocystostomy is performed under endoscopic guidance with intracorporeal suturing using interrupted 5-0 or 6-0 poliglecaprone or polydioxanone sutures. A ureteral stent is not routinely used except for selected patients undergoing bilateral ureteral reimplantation or those with megaureters requiring tapering ureteroplasty. The port sites are then closed with the previously inserted hitching U-stitch upon completion of the procedure. Bladder drainage by a urethral catheter is maintained for 24 hours post-operatively.

### Our Experience and Results

Over a 11-year period from 1999 to 2010, 133 patients (92 boys, 41 girls) aged 5 months–16 years (mean: 5.1 years) with primary vesicoureteral reflux that was associated with a history of recurrent urinary tract infections and/or multiple pyelonephritic renal scarring, underwent endoscopic Cohen cross-trigonal ureteric reimplantation with CO<sub>2</sub> pneumovesicum. Of these, 45 had bilateral reflux giving a total of 178 refluxing ureters. Reflux grades were: 3% grade 2, 21% grade 3, 46% grade 4, 31% grade 5. Eighteen patients suffered from persistent VUR after failed subureteric Deflux injection. Ten patients had simultaneous tailoring ureteroplasty for grossly dilated refluxing megaureters. In addition, 12 refluxing ureters were associated with large paraureteric diverticulum that was excised simultaneously at the time of ureteric reimplantation.

Endoscopic cross-trigonal ureteral reimplantation under CO<sub>2</sub> pneumovesicum was successfully completed in all except one patient, who had displacement of a working port into the extravascular space after completion of the ureteral reimplantation. This resulted in a conversion to a small vesicotomy for closure of the mucosal defect. Blood loss was minimal in all cases. The mean operating time was 126 minutes (range: 80-245 minutes), being 108 minutes for unilateral cases and 165 minutes for bilateral cases. Similar to other novel techniques, there was a very steep learning curve, with a significantly longer operating time for the first few cases than in subsequent cases. The mean hospital stay was 1.9 days (range: 1 - 6 days).

In the very early part of the series when the ports were not routinely secured to the bladder wall as described above, displacement of the port outside the bladder wall occurred in 4 patients. This resulted in gas leakage into the extravascular space, with compromise of the intravesical space and endoscopic vision and thus a prolongation of the operating time, although the procedure could still be completed without open conversion in 3 of the 4 cases. Three boys developed mild to moderate scrotal and suprapubic emphysema immediately post-operatively, which subsided spontaneously within 24 hours. Persistent mild haematuria for over 72 hours, which settled spontaneously, was noted in 5 patients. One patient developed fever associated with ipsilateral hydronephrosis one week post-operatively, suggestive of anastomotic stricture. This was managed by cystoscopic insertion of a double-J ureteric

***Over a 11-year period from 1999 to 2010, 133 patients (92 boys, 41 girls) aged 5 months–16 years (mean: 5.1 years) with primary vesicoureteral reflux that was associated with a history of recurrent urinary tract infections and/or multiple pyelonephritic renal scarring, underwent endoscopic Cohen cross-trigonal ureteric reimplantation with carbon dioxide pneumovesicum.***

*(continued on next page)*

## Pneumovesicoscopic Surgery (continued from previous page)

stent. The stent was subsequently removed 2 months afterwards and the child remained well with no further signs of obstructive uropathy. Nine patients developed febrile UTI post-operatively. There were no other serious complications and all other patients recovered uneventfully and remained well. Of note, bladder spasms were minimal after the procedure, and were especially so with early removal of the urinary catheter. In most cases oral analgesics alone were sufficient and intravenous injections were only very occasionally required. All children returned to normal activities within a week from surgery.

Follow-up voiding cystogram was routinely performed in the early part of the series and was obtained in 87 patients (118 refluxing ureters) 3-6 months post-operatively. Complete resolution of reflux was observed in 82 patients (113 ureters, 96%). Among patients with residual reflux, only one boy with Grade V reflux had persistent reflux unchanged. Reflux was downgraded to either grade I or II in the other 4 patients. Nine patients (6.7%) developed a febrile urinary infection 2-11 months after the ureteral reimplantation. All other patients remained asymptomatic and well at a mean follow-up of 2.3 years (range: 10 months – 10.5 years).

### Discussion

As the bladder is an extraperitoneal organ with its own muscular wall, surgical access for MIS requires special technical modifications as contrast to other conventional laparoscopic surgery for an intraperitoneal organ. Especially in young infants, the bladder wall can be easily detached from the abdominal wall thereby leading to gas retention in the extravascular space. This in turn can result in compression of the bladder, which will lead to diminution of the intravesical operative space and increasing difficulty for further surgical manipulation. The key to success for a pneumovesicoscopic procedure therefore hinges on anchoring the trocars securely to the bladder as well as to the abdominal wall using the hitch stitch as previously described. This will help to avoid trocar displacement and gas leakage into the extravascular space, the two main factors for surgical failure and conversion. Care must be taken also to avoid over-exertion of force and separation of the bladder wall from the abdominal wall during trocar insertion. During the operation the surgeon must also be aware of the possibility of gas leakage. Early detection and timely relief of gas leak using a simple venous cannula can provide adequate decompression and allow continuing of the procedure.

With increase in experience we have successfully applied the pneumovesicoscopic technique to all other complex intravesical reconstructive procedures including tapering ureteroplasty for megaureters, excision of Hutch diverticulum and large ectopic ureteroceles, bladder base and bladder neck reconstruction procedures,...etc. In addition, the pneumovesicoscopic ureteric

reimplantation technique can be used simultaneously with Deflux subureteric injection in the same session. Our principle is to select the most appropriate MIS treatment modality according to reflux grading and individual anatomical anomalies to optimize surgical outcome. For mild grades VUR (grades II - IV) we would use cystoscopic subureteric Deflux injection as the treatment of choice, but with an attempt to avoid any unfavorable anatomical anomalies that would render injection difficult, e.g. a large paraureteric diverticulum, a stenosed or very laterally positioned ureteric orifice, ectopic ureteric orifice, ...etc. For very severe grades (grade V +/- bilateral IV) +/- anatomical anomalies or repeated injection failures, we would adopt the pneumovesicoscopic ureteric reimplantation technique as the treatment of choice. Parental counseling and consent is obtained so that the final decision on the surgical option can be made intra-operatively based on the cystoscopic findings to exclude any unfavorable anatomies in order to best optimize the surgical outcome. For a child with asymmetric reflux, subureteric Deflux injection and pneumovesicoscopic ureteric reimplantation can be performed on contralateral ureters simultaneously in one setting. Using this approach, we have been able to achieve very high cure rates (>90% reflux resolution) for all grades of VUR with one general anesthetic session and one single treatment.

In summary, our early experience illustrates that endoscopic intravesical ureteric mobilization and cross-trigonal ureteric reimplantation can be safely and effectively performed with routine laparoscopic surgical techniques and instruments under CO<sub>2</sub> insufflation of the bladder. The pneumovesicoscopic technique is very versatile and can be used for any other intravesical reconstructive procedures and also in conjunction with subureteric Deflux injection.

### References

1. McCool AC, Joseph DB. Postoperative hospitalization of children undergoing cross-trigonal ureteroneocystostomy. *J Urol* 1995; 154: 794-6.
2. Marotte JB, Smith DP. Extravesical ureteral reimplantation for the correction of primary reflux can be done as outpatient procedures. *J Urol* 2001; 165: 2228-3.
3. Puri P, Granata C. Multicenter survey of endoscopic treatment of vesicoureteral reflux using polytetrafluoroethylene. *J Urol*. Sept 1998. 160(3-II): 1007-1011.
4. Lackgren G, Stenberg A, Wahlin N, et al. Long-term follow-up of children treated with dextranomer/hyaluronic acid co-polymer for vesicoureteral reflux. *J Urol* 2001; 166: 1887-92.
5. Okamura K, Kato N, Tsuji Y, Ono Y, Ohshima S. A comparative study of endoscopic trigonoplasty for vesicoureteral reflux in children and adults. *J Urol* 1999; 6: 562-6.
6. Atala A, Kavoussi LR, Goldstein DS, Retik AB, Peters CA. Laparoscopic correction of vesicoureteral reflux. *J Urol* 1993; 50: 748-51.
7. Lakshmanan Y, Fung LC. Laparoscopic extravesicular ureteral reimplantation for vesicoureteral reflux: recent technical advances. *J Endourol* 2000; 14: 589-93.
8. Lipski BA, Mitchell ME, Burns MW. Voiding dysfunction after bilateral extravesical ureteral reimplantation. *J Urol* 1998; 159: 1019-21.
9. Olsen LH, Deding D, Yeung CK, Jorgensen TM. Computer assisted laparoscopic pneumovesical ureter reimplantation a.m. Cohen: initial experience in a pig model. *APMIS Suppl* 2003; 109: 23-5.

## II. MINIMALLY INVASIVE APPROACH TO AUGMENTATION CYTOPLASTY

### Laparoscopic Assisted Approach for Bladder Augmentation

Daniel P. Casella, MD and Steven G. Docimo, MD

Division of Pediatric Urology, Children's Hospital of Pittsburgh,  
University of Pittsburgh School of Medicine, Pittsburgh, Pennsylvania

Performing complex reconstructive surgery while minimizing cosmetic impact and overall morbidity has long been the goal of pediatric urologists. It was not long after the development of laparoscopic clip applicators and stapling devices that the first pure laparoscopic bladder augmentation, a gastrocystoplasty, was performed.<sup>1</sup>

Given the relative infancy of laparoscopic instrumentation and large amount of intracorporeal suturing, the operative time was 10 hours and 55 minutes. Despite the prolonged operative time, the patient had a benign postoperative course and an excellent outcome. Following this initial experience, we adopted a hybrid approach. In our combined approach, the initial access, lysis of adhesions and harvesting of stomach, bowel or ureter is performed laparoscopically prior to creation of a low Pfannenstiel or lower midline incision and traditional open bladder reconstruction. In addition to initial dissection, for those with the requisite laparoscopic experience, major portions of the reconstruction including creation of Mitrofanoff stomas, ACE stomas, and nephrectomy prior to ureteral augmentation can all be performed laparoscopically.

The first series of 8 patients was reported in 1999 with only one patient requiring narcotic at discharge, and a subsequent comparison of the first 11 stoma cases to comparable open procedures demonstrated equivalent operating times with a decrease in mean hospitalization of 3.3 days.<sup>2,3</sup> No formal quantification of cosmetic satisfaction was included, but subjective improvement was noted in all cases. The series was updated in 2004 at which time 31 patients had been treated with a mean hospitalization of 6 days, and similar outcomes to traditional open procedures at a mean follow-up of 32 months.<sup>4</sup> Despite the fact that 25 out of the 31 patients in our series had a history of abdominal procedures (including 16 with a history of ventriculoperitoneal shunt), only one case required conversion to an open procedure due to dense adhesions.

#### Benefits

The most obvious benefit to the combined approach is improved cosmesis. Three laparoscopic ports are typically used with a 10-12mm umbilical port, a 2-5mm epigastric port and a 10mm port placed at the lateral edge of the future Pfannenstiel incision, or at the site of a planned second stoma. (Figure 1) Ultimately the primary catheterizable stoma is placed through the umbilical port and the lower abdominal port is incorporated into the Pfannenstiel incision, leaving the 2-5mm epigastric port as the sole exposed incision. Patients with myelodysplasia often have the malrotation of the cecum and an altered body habitus<sup>5,6</sup> making access into the upper abdominal cavity difficult from a low midline or Pfannenstiel incision. Access to the upper abdomen is straightforward with laparoscopy and eliminates the need for an additional or extension of a low midline incision. Adhesions following open procedures are a morbid and

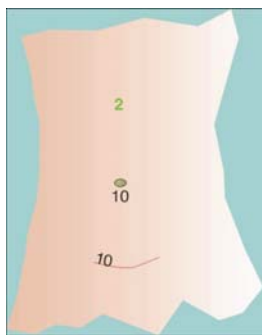


Figure 1

costly complication in a pediatric population.<sup>7</sup> Laparoscopy has been demonstrated to decrease post-operative adhesions,<sup>8,9</sup> in addition to decreasing pain and overall morbidity of major procedures. Many patients who require bladder augmentation will also require reconstruction of the bladder neck or surgical intervention to increase outlet resistance. Bladder neck reconstruction or sling placement are challenging to perform through a pure laparoscopic or robotic approach, but are accomplished through a small lower abdominal incision using techniques familiar to all reconstructive urologists.

#### Cons

Many patients undergoing lower urinary tract reconstruction have a history of prior of abdominal procedures, and dense adhesions may rarely prohibit laparoscopy. The initial dissection does require basic laparoscopic skills, however performing the reconstruction extracorporeally avoids the need for advanced laparoscopic skills (and their requisite learning curve). This approach also requires a healthcare facility with basic laparoscopic instrumentation and support staff, which happily, are widely available.

#### Summary

Given the wide variety of patients, complexity of the procedure and rapidly advancing technology, the approaches for lower urinary tract reconstruction are continually improving. When compared to traditional open procedures, the combination of laparoscopy and open reconstruction through a small lower abdominal incision provides a significant improvement in cosmetic outcomes, similar operative times, decreased post-operative stay and at least equivalent long term outcomes. No matter what the ultimate degree of adoption of pure laparoscopic or robotic lower tract reconstruction might be, there is no longer any reason to subject the majority of our patients to a large abdominal incision in order to provide a compliant, continent bladder that is easily catheterized.

#### References

1. Docimo, S.G., et al., *Laparoscopic bladder augmentation using stomach*. *Urology*, 1995. 46(4): p. 565-9.
2. Hedician, S.P., P.G. Schulam, and S.G. Docimo, *Laparoscopic assisted reconstructive surgery*. *J Urol*, 1999. 161(1): p. 267-70.
3. Cadeddu, J.A. and S.G. Docimo, *Laparoscopic-assisted continent stoma procedures: our new standard*. *Urology*, 1999. 54(5): p. 909-12.
4. Chung, S.Y., K. Meldrum, and S.G. Docimo, *Laparoscopic assisted reconstructive surgery: a 7-year experience*. *J Urol*, 2004. 171(1): p. 372-5.
5. Brown, S.F., *Congenital malformations associated with myelomeningocele*. *J Iowa Med Soc*, 1975. 65(3): p. 101-4.
6. Baker, R.H. and W.J. Sharrard, *Correction of lordoscoliosis in spina bifida by multiple spinal osteotomy and fusion with dwyer fixation: a preliminary report*. *Dev Med Child Neurol Suppl*, 1973: p. Suppl 29:12-23.
7. Ray, N.F., et al., *Economic impact of hospitalizations for lower abdominal adhesiolysis in the United States in 1988*. *Surg Gynecol Obstet*, 1993. 176(3): p. 271-6.
8. Moore, R.G., et al., *Adhesion formation after transperitoneal nephrectomy: laparoscopic v open approach*. *J Endourol*, 1995. 9(3): p. 277-80.
9. Moore, R.G., et al., *Postoperative adhesion formation after urological laparoscopy in the pediatric population*. *J Urol*, 1995. 153(3 Pt 1): p. 792-5.

# Laparoscopic Approach for Bladder Augmentation

Armando J. Lorenzo, MD MSc FRCSC FAAP FACS, Pediatric Urologist, Assistant Professor  
Division of Urology, Hospital for Sick Children, University of Toronto, Toronto, Ontario, Canada

Laparoscopic (i.e. “traditional” laparoscopy) and robotic-assisted laparoscopic procedures have been exciting, relatively recent additions to the surgical armamentarium of surgeons, including those who specialize in the management of pediatric patients. The promises and ideals of minimally invasive interventions have allowed for the fast-paced introduction of many adaptations of classic open surgical procedures. A good number of examples have successfully gone through this revolution, now widely accepted by many as the new standard. Based on better cosmetics results and quicker recovery—along with the frequent (yet unfounded) perception that outcomes will be better because of the novelty behind the technology—providers and families have embraced minimally invasive alternatives. Although often lacking rigorous high-level comparative studies to back it up, many common conditions—including ureteropelvic junction obstruction and non-palpable testicles—are addressed employing these surgical innovations. Other work presented in *Dialogues* discusses management of many of these conditions and highlights the impact of technological advances.

Conceptually, irrespective of the indication, both standard and robotic-assisted laparoscopic approaches are better seen as tools to conduct a procedure, rather than separate surgical techniques. Although there are some occasional required modifications, for the most part the goal is to mimic the open counterpart. Thus, when considering minimally invasive procedures, we should critically ask ourselves if these are truly better than other reasonable or more established ones aimed at reaching the same goal, and—if so—in what sense. Furthermore, the transition from older open techniques along with the associated learning curve and possible incurred additional complications has to be carefully considered. Herein, I would like to reflect on this phenomenon specifically when dealing with children considered to be candidates for augmentation cystoplasty, a relatively uncommon scenario most frequently encountered in patients with reduced bladder capacity experiencing the aftermath of neurogenic insults (such as myelomeningocele) or congenital lower urinary tract conditions (such as bladder exstrophy).

The first question we should ask ourselves is *Why?* At the risk of broadening the topic too much, I would not only question the rationale for minimally invasive over open procedures, but more importantly the indication for augmentation cystoplasty and how to avoid or delay it as much as possible. In addition, although strictly speaking laparoscopic techniques can be labelled as minimally invasive by virtue of the abdominal wall point-of-entrance dimensions, the [augmentation] procedure itself is anything but. The particularly impressive large experience published by the Indiana group attests to the potential complications and morbidity, many far from inconsequential, and some clearly life threatening.<sup>1,2</sup> Even though a strong case can be made for this morbidity to be incurred in order to protect the upper tracts and prevent renal insufficiency, if the sole or main indication for surgery is urinary incontinence, quality of life issues have to be heavily contrasted against worrisome data from these and other reports. In other words, the sole goal of attaining social continence brings up the difficult to balance impact on theoretically improving future quality of life against complications (procedure-related, short-term, or long-term). It is hard to defend someone dying or experiencing serious morbidity from an intervention aimed at improving continence. In addition, looking ahead it is not unreasonable to expect further problems as this population ages (Fig 1). Therefore, my personal philosophy on the topic is to exhaustively try to find ways to minimize the need to conduct an enterocystoplasty by carefully exploring options that limit exposing gastrointestinal mucosa to the urinary tract.<sup>3,4</sup> As a result of this questioning process, we can open the scope of “minimally invasive” to emerging selected strategies, such as intra-vesical administration of onabotulinum toxin A (which may further address decreased compliance and persistent detrusor overactivity<sup>4</sup>) or exclusively addressing an incompetent bladder neck (which may be a good fit for robotic and laparoscopic techniques), coupled with optimized anticholinergic treatment.<sup>3</sup>

The next step is to question, *How?* Is it truly better, or even equivalent, to conduct augmentation cystoplasties laparoscopically? This question has to be addressed in the context of the patient population that is being targeted and the rather common need for concomitant procedures (such as crafting a catheterizable channel for alternative or sole access to the urinary reservoir, ureteral reimplantation, and bladder neck procedures). Indeed, adding on other interventions becomes a more difficult proposition for current “pure” laparoscopic technology. As such, a “bridge” approach can be brought into the picture, whereby the surgeon tries to exploit the most favorable aspects of open surgery and laparoscopy in order to maximize efficiency and good outcomes

**Thus, when considering minimally invasive procedures, we should critically ask ourselves if these are truly better than other reasonable or more established ones aimed at reaching the same goal, and—if so—in what sense.**

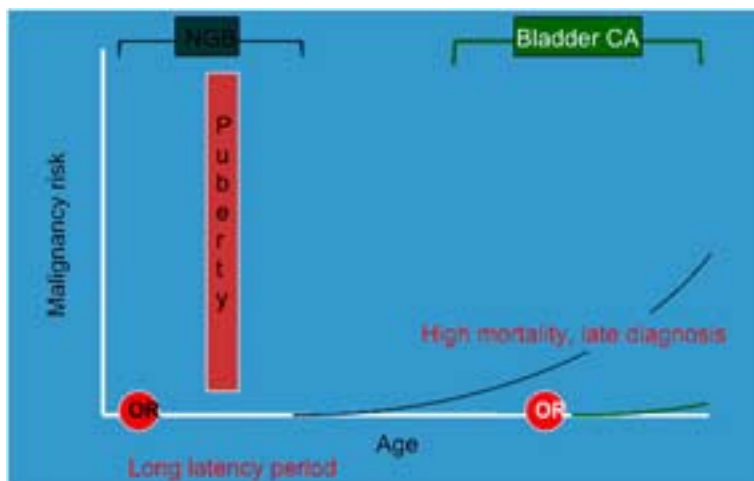


Figure 1: Theoretical representation of complication rates (in this case malignancy) following enterocystoplasty. Although debatable,<sup>14</sup> any increase is likely to be time-dependent and thus impacted by the patient's life expectancy.

(continued on next page)

## Laparoscopic Approach for Bladder Augmentation *(continued from previous page)*

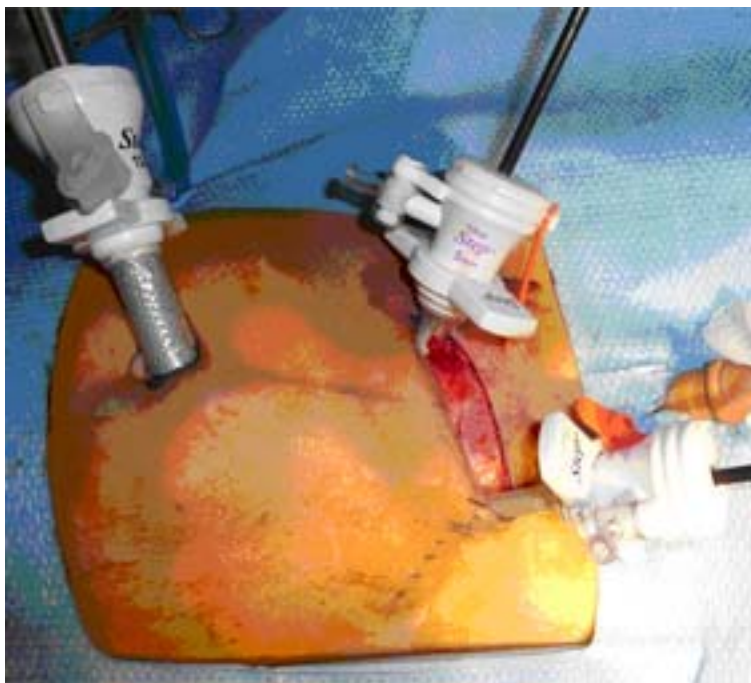while embracing some of the concepts of minimally invasive surgery (i.e. lap-assisted).<sup>5,6</sup> A Pfannenstiel-type incision along with camera access through the umbilicus (Fig 2) permits laparoscopic mobilization, limited dissection, and placement of the selected bowel segment near the pelvis while providing great (and well concealed) open access to the bladder. This is favorable not only for completing cumbersome parts of the intervention following traditional open surgical steps, but also advantageous for bladder neck and ureteral procedures. The umbilical port access can be used as the stoma site for a Mitrofanoff, Monti or MACE channel (if needed). Similarly, in the rare situation where a ureterocystoplasty is considered, the non-functioning kidney can be dissected laparoscopically.<sup>7</sup> Although not impossible, these additional procedures, such as ureteral reimplantation or bladder neck reconstruction, can be attempted laparoscopically or with the robot. Nevertheless, they remain technically challenging, while more straightforward following an open approach.

Lastly, we should ponder on *Who* is a good candidate. Just like any other procedure, variations in the selected approach must be tailored to the specific patient. Akin to different open surgical strategies adapted to the child, it is unreasonable to expect that laparoscopic or robotic assisted interventions can be offered to all patients without adjustments or modifications. It is critical to consider that many of the potential candidates are also affected by important co-morbidities, some that may be of importance when considering anesthetic and positioning issues related to laparoscopy and robotic surgery; have little to no interest in potential cosmetic advantages; or have already undergone previous surgeries which may make minimally invasive access more difficult. An impaired sensory level may mitigate any analgesic benefit or, in some cases, may be advantageous only for lower abdominal incisions while higher-placed port sites go through sensate areas. Quicker

recovery may not always apply, as the process is not only dependent on healing skin, fascia and muscle at entry wounds, but also on parts of the procedure that are partially independent of the approach (such as bowel manipulation and anastomosis). Similarly, cardio-pulmonary compromise, presence of hydrocephalus with or without shunt, and abnormal body habitus are individual considerations, which may favor open over laparoscopic surgery. In addition, duration of anesthesia (time which may be appreciably longer with laparoscopy) has to be considered and presented to potential candidates coupled with the unknown cumulative effect the employed agents may have on brain function.<sup>8,9</sup>

It is striking to see the rather limited number of publications on the topic of minimally invasive augmentation cystoplasty.<sup>10</sup> Even after considering patients of all age groups and irrespective of the laparoscopic technology utilized, numbers are modest and rival the number of modifications or technological innovations employed. Aside from the small number of children that are candidates, this may be a reflection of the demanding technical challenges of the procedure, taxing impact on resources, or publication bias due to less than favorable outcomes when independently attempting to reproduce a published report. As suggested by Gundeti,<sup>11</sup> when evaluating any new procedure we must critically ask 4 important questions: Is it feasible? Is it safe? Is it effective? And, does it have any significant advantages compared with its predecessor? These should be raised for all novel interventions, including laparoscopic augmentation cystoplasty, by contrasting what can be done with what should be done in the child's best interest. This requires evidence. Nevertheless, drastically different from more common situations, enterocystoplasty and associated procedures are fortunately uncommon. Thus, data are limited. I will then spare you the frequently uttered yet almost meaningless call for randomized controlled trials. It is unrealistic to expect one any time soon. After all, these studies are virtually uniformly absent in the pediatric urological literature. Alternatively, well-constructed prospective observational databases may be the answer to assess the advantages and disadvantages of laparoscopy for this particular indication. The most promising pediatric data in terms of thoroughness, a systematic progression of the experience with robotic assisted procedures described by the University of Chicago group,<sup>11</sup> is still premature and somewhat limited in terms of compelling benefits. At this point the few available case reports and small series describe surgical times in excess of 6-8 hours and outcomes are barely mature enough to declare satisfactory early results. Efforts to systematically study this application are clearly needed before superiority is assumed and equipoise is compromised.

As previously implied, I would suggest that the concept of invasiveness for this particular situation clearly goes beyond the size and number of skin incisions, and includes the goal of the surgical procedure. At best, laparoscopy and robotic-assistance offer a means to provide less invasive rather than "minimally" invasive, which conceptually may not necessarily be the case. The trade-off is huge, balancing important short- and long-term risks with arguably soft benefits, very much dependent on the patient's perception on the impact incontinence and independence has on quality of life. At the risk of sounding overtly simplistic, the ultimate minimally invasive procedure is *no* procedure, closely followed by interventions that prevent or delay the need for major reconstruction. We should consider taking the concept of invasiveness out of the artificial confines of the rather brief period of time spent in the operating room, extending it into the overall plan for management since diagnosis.



*Figure 2: Port placement for lap-assisted lower urinary tract reconstruction. Notice that working ports are strategically placed under direct laparoscopic visualization with the skin entry points limited to the area of the small Pfannenstiel incision.*

*(continued on next page)*



## Laparoscopic Approach for Bladder Augmentation *(continued from previous page)*

Should we push the envelope? Yes, but carefully, and critical to the assumption that new is always better than old and proven. Just because something can be done doesn't mean that it should be done. Patient selection is obviously critical.

Without doubt, many arguments can be made for or against, and in the absence of strong comparative data, it all depends on which perspective is taken. Some surgeons may be in favor, and some families are certainly attracted to exciting new approaches. Others are more cautious; embracing things more slowly, while often lamenting the lack of good evidence and paucity of properly conducted trials. Although this can be perceived as trivial, the introduction of novel devices is not always met with equivalence or superiority to older time-proven ones. A clear recent example is seen around the controversy around types of hip replacement materials.<sup>12</sup> Thus, I propose that tempering enthusiastic acceptance of new technology is sometimes just as wise as jumping in and quickly trialing them.

Perhaps considered by some a flashback from views presented by initial opponents of laparoscopy, I would carefully embrace current laparoscopic or robotic adaptations for the management of most patients in need of bladder augmentation. This may come as a surprise, as our group reported one of the first laparoscopic augmentation cystoplasty cases in the pediatric urology literature.<sup>13</sup> My personal view on the topic is that the application of laparoscopy and robotic surgery should be reserved for a selected small group of children, that alternative "minimally invasive" interventions should be exhausted before proceeding to place bowel mucosa in constant contact with urine, and that the future will hopefully bring more appealing strategies which may make the topic here in review, obsolete.

### References

1. Metcalfe PD, Casale AJ, Kaefer MA, et al. Spontaneous bladder perforations: a report of 500 augmentations in children and analysis of risk. *J Urol* 2006;175(4):1466–70; discussion 1470–1.
2. Metcalfe PD, Cain MP, Kaefer M, et al. What is the need for additional bladder surgery after bladder augmentation in childhood? *J Urol* 2006;176(4 Pt 2):1801–5; discussion 1805.
3. Snodgrass W, Barber T, Cost N. Detrusor compliance changes after bladder neck sling without augmentation in children with neurogenic urinary incontinence. *J Urol* 2010;183(6):2361–2366.
4. Gamé X, Mouracade P, Chartier-Kastler E, et al. Botulinum toxin-A (Botox) intradetrusor injections in children with neurogenic detrusor overactivity/neurogenic overactive bladder: a systematic literature review. *J Pediatr Urol* 2009;5(3):156–164.
5. Caddeu JA, Docimo SG. Laparoscopic-assisted continent stoma procedures: our new standard. *Urology* 1999;54(5):909–912.
6. Chung SY, Meldrum K, Docimo SG. Laparoscopic assisted reconstructive surgery: a 7-year experience. *J Urol* 2004;171(1):372–375.
7. Cilento BG, Diamond DA, Yeung CK, Manzoni G, Poppas DP, Hensle TW. Laparoscopically assisted ureterocystoplasty. *BJU Int* 2003;91(6):525–527.
8. Davidson AJ. Anesthesia and neurotoxicity to the developing brain: the clinical relevance. *Paediatr Anaesth* 2011;21(7):716–721.
9. Zou X, Liu F, Zhang X, et al. Inhalation anesthetic-induced neuronal damage in the developing rhesus monkey. *Neurotoxicol Teratol* 2011;33(5):592–597.
10. Traxel EJ, Minevich EA, Noh PH. A review: the application of minimally invasive surgery to pediatric urology: upper urinary tract reconstructive procedures. *Urology* 2010;76(1):115–120.
11. Gundeti MS, Acharya SS, Zagaja GP, Shalhav AL. Paediatric robotic-assisted laparoscopic augmentation ileocystoplasty and Mitrofanoff appendicovesicostomy (RALIMA): feasibility of and initial experience with the University of Chicago technique. *BJU Int* 2011;107(6):962–969.
12. Smith AJ, Dieppe P, Vernon K, Porter M, Blom AW, on behalf of the National Joint Registry of England and Wales. Failure rates of stemmed metal-on-metal hip replacements: analysis of data from the National Joint Registry of England and Wales. *Lancet* 2012;
13. Lorenzo AJ, Cerveira J, Farhat WA. Pediatric laparoscopic ileal cystoplasty: complete intracorporeal surgical technique. *Urology* 2007;69(5):977–981.
14. Higuchi TT, Granberg CF, Fox JA, Husmann DA. Augmentation cystoplasty and risk of neoplasia: fact, fiction and controversy. *J Urol* 2010;184(6):2492–2496.

## Robotic Approach for Bladder Augmentation

**Pankaj Dangle Mch, Urology Resident and Mohan S. Gundeti MB MCh FEBU FRCS (Urol) FEAPU Associate Professor of Urology in Surgery, Pediatrics and Ob/ Gyn, Director, Pediatric Urology Director, Center for Pediatric Robotic and Minimal Invasive Surgery The University of Chicago Medicine & Biological Sciences**

Minimally invasive approach has rapidly evolved from pure laparoscopy to robotic technology. Augmentation cystoplasty has a well-defined role in both neurogenic and non-neurogenic bladder dysfunction.<sup>1,2</sup> The continent catheterizable channels are performed with or without this to achieve social urinary continence and protect upper urinary tracts.

As common to all new technologies, routine use of laparoscopy was challenged, especially in pediatric patients. Ever since, laparoscopy has gained increased acceptance in pediatric population with its projected benefits of early recovery, decreased postoperative pain, shorter hospital stay and improved cosmesis. Though popular, its pediatric application was somewhat difficult due to restriction on instrumentation and steep learning curve, especially in complex reconstructive cases. Many procedures, such as orchiopexy, nephrectomy and cyst decortication, have been performed safely and effectively with comparable outcomes to the open surgery.<sup>3</sup> The reconstructive procedures like pyeloplasty and reimplantation, however, have been practiced by few experts in field; therefore sporadic case reports existed in literature regarding augmentation cystoplasty and catheterizable channels.<sup>4</sup> One of the important limitations for conventional laparoscopic surgery

that could be attributed to the pediatric patient is limited working space, as well as surgeon fatigue with prolonged surgical time and the intricacy of the suturing and handling of the tissue.

Robotic technology from the Da Vinci surgical system (Intuitive Surgical, Sunnyvale, USA) is a new technological invention, which has gripped the urological surgeons as a tool to bridge the gap from conventional laparoscopy and open surgery. Due to its inherent advantages of magnification, freedom of movements with endowrist, precision, tremor control, decreased surgeon fatigues are some of the promising benefits compared to conventional laparoscopy.

Though many adult urology programs are adopting the technology at much faster rate, its use in pediatric urology is slowly evolving. With advancing experience, application of the technology has been extended from upper urinary tract to more complex lower urinary tract reconstructions currently at select centers in USA and slowly evolving in rest of the world.

Complete intracorporeal laparoscopic enterocystoplasty has been described by Lorenzo *et al.* in adults<sup>5</sup> and in one pediatric patient.<sup>6</sup> Similarly, individual cases have been reported of laparoscopic<sup>7,8</sup> and

*(continued on next page)*

## Robotic Approach for Bladder Augmentation *(continued from previous page)*

robotic-assisted<sup>9</sup> Mitrofanoff appendicovesicostomy, but robotic-assisted augmentation enterocystoplasty or combined enterocystoplasty and Mitrofanoff appendicovesicostomy with complete intracorporeal suturing without stapling has not yet been described. The limiting step has been the complex multiple steps involved in the procedure and the morbidity involved with potential leak of bowel anastomosis, if happens as described in a porcine model study.<sup>10</sup>

At our institution with the senior author's (MSG) experience in open complex reconstruction, laparoscopy and evolving robotic upper urinary tract reconstruction and augmented with the lab experience, we have instituted this procedure successfully first time in the pediatric literature.<sup>11</sup>

Our standard surgical technique is well described previously<sup>12</sup>, some of the important high points are as follows. No preoperative bowel preparation is given. After preoperative cystoscopic stent placement (only in earlier cases—this is not our current practice) the patient is positioned in semi-lithotomy and Trendelenburg position. Our trocar placement follows with an open Hassan's technique (12mm umbilical trocar), two 8mm ports are placed 7cm lateral from midline with an assistant ports 7cm from robotic arms (12mm) left and 5mm on right side (Fig 1). After complete evaluation of the peritoneum cavity and appendix, 20cm of ileum is marked and presence of adequate mesentery is ensured before mesenteric window is created. Once the intracorporeal bowel anastomosis is completed, appendix is handled by placing stay suture at the tip. Appendicular mesenteric window is created; care is taken to preserve the blood supply, base is excised and a 4 cm detrusorotomy is performed on the right posterior wall of bladder. Tip of appendix is spatulated and anastomosed to bladder (1 cm) in a continuous fashion and detrusor imbrications (Fig 2). Recently we have modified this part of the procedure and now we perform the intravesical technique for appendix anastomosis. After incising the bladder in coronal fashion from right to left lateral wall both the ureteral stents and 8 fr feeding tube in the appendicovesicostomy is secured with absorbable suture. Ileum is opened on anti-mesenteric border and anastomosed with care being taken to avoid mesenteric twisting. Procedure is completed by placing an 18Fr suprapubic tube in native bladder in the left lower quadrant before completing the anastomosis (Fig 3). A right iliac fossa incision is made in the line of future appendicovesicostomy stoma or the assistant port could be used for this purpose. In some cases we bring the appendix stoma through umbilical camera port.

As reported previously, of 6 patients who underwent robotic –assisted laparoscopic augmentation ileocystoplasty and Mitrofanoff appendicovesicostomy (RALIMA) one required open conversion secondary to failure to progress. In this cohort; average age was 9.75 years<sup>8-11</sup>, average operative time was 8.4h<sup>6-11</sup>, and average estimated blood loss was 150mls (85-200ml), with no intraoperative complications. All patients were managed with acetaminophen and ibuprofen with codeine on as needed basis; no patient received morphine postoperatively. All except one patient who had temporary ileus, the interval to oral fluid intake was within 8h and to soft diet was 24h postoperatively. All patients were ambulated to out of bed and into chair for wheelchair-bound patients on postoperative day 2-3 with discharge between 5-7 days.<sup>13, 14, 17-19</sup>

This new surgical approach is feasible with complete intracorporeal reconstruction. Based on our initial and continued experience it appears to be safe with minimal blood loss, no intraoperative complications with early ambulation and early return of bowel function. We

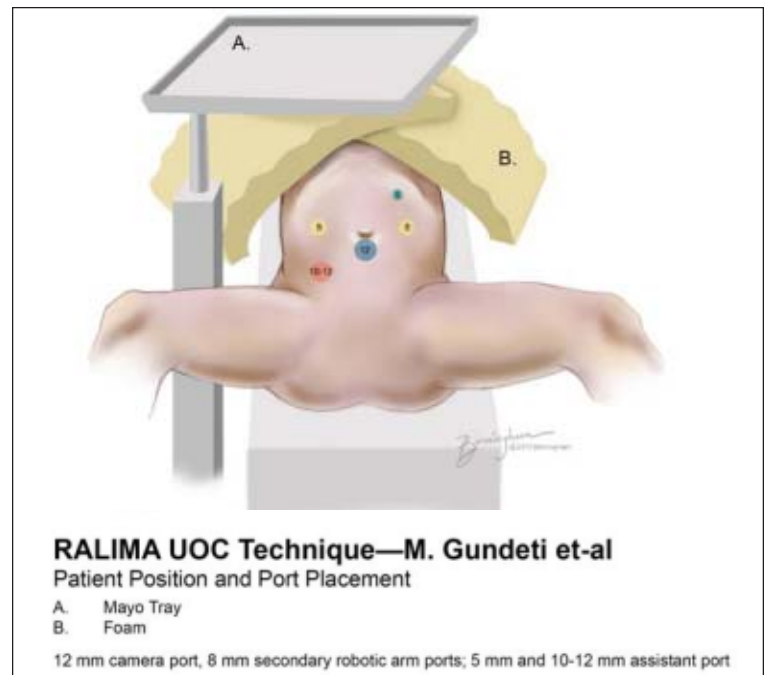


Figure 1 Port placement

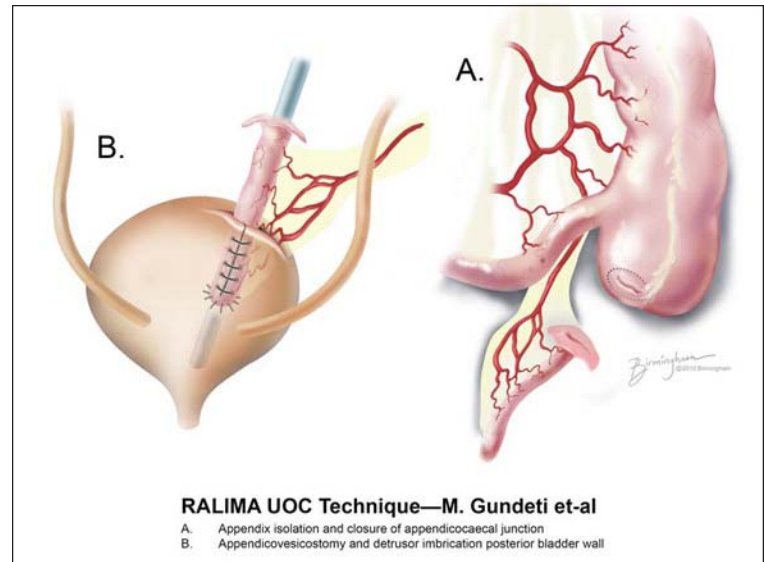


Figure 2 Completed appendicovesicostomy with bladder imbrications

continue to use this approach for augmentation cystoplasties with or without appendicovesicostomy and the operative times continue to decrease, with pain control being managed by oral pain medication, none needed epidural analgesia.<sup>13</sup>

Similarly we have seen same benefits for the children undergoing Robotic assisted laparoscopic appendicovesicostomy (RALIMA) procedures. In our study of evaluating continence outcomes in patients undergoing Robotic Mitrofanoff appendicovesicostomy over 20 month follow-up only 1 patient had incontinence secondary to inadequate detrusor backing corrected later by injection of the bulking agents.<sup>14</sup>

So the question is do we move to the new technology and if so why? To answer the question it is very important to critically review its application, comparing with open series, review the cost and its surgical outcome measured by success.

*(continued on next page)*

## Robotic Approach for Bladder Augmentation *(continued from previous page)*

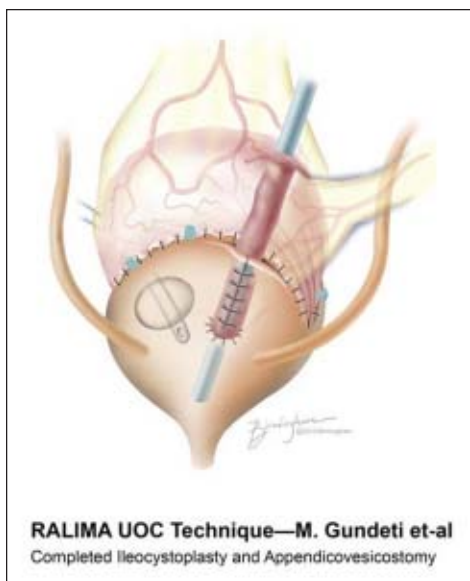


Figure 3 Completed augmentation cystoplasty

ence the operative complications have been minimal though our data needs to be matured to see the long-term complications as discussed earlier.

Proponents of the open procedure argue against minimally invasive approach based on the learning curve, proficiency, increased surgical time and cost involved in establishing a pediatric robotic program. But this is surgical invention - evolution curve and it will need few more years and numbers to match these outcomes, as the adult population has seen for the radical prostatectomy or nephrectomy.

In regards to the cost, though the direct head to head comparison is difficult, if we take out the capital investment, reduced inpatient stay, no epidural analgesia, less pain medication and human capital gains (of parents) associated will be comparable.<sup>16, 17</sup>

Currently one of the major dogmas of robotic surgery is the operative time and this will eventually improve, once we overcome the significant learning curve. In our brief experience we suggest, apart from adequate training in robotics, through understanding of the technology and troubleshooting, it is vital to follow the process of "Learning curve". This may include watching the experts perform surgery, attending live operative sessions, discussion, porcine model training, proctor - mentoring, starting with non complex case in the beginning and slowly advancing with appropriate complex cases is most important part of the successful program.<sup>18</sup>

One of the critical parts of the surgical outcome is response to surgical stress manifested by post-operative pain. Pain management is challenging because of limitation of regional analgesia and narcotic analgesia augments the neurogenic bowel component, the use of oral medication in our series has been another advantage to overcome this factor.

Other possible benefit is avoiding the insensible losses from open peritoneal space in prolonged open cases. Direct tissue handling can be minimized with robotic access, with potential for decreasing post operative ileus, abdominal distension, and decreased wound complications due to small size incision and the chest infection (atelectasis) secondary to lack of pain with limited respiratory excursion.

Kispal et al in their cohort of 86 patients with predominant myelomeningocele (n=43) and exstrophy-epispadias complex (n=24) population followed over 20 years reported 105 complications. Stone formation was the most common (n=34) followed by stomal complications, a total of 91 interventions were reported.<sup>15</sup> In most series with a long-term follow-up a high rate of complication ranging between 36-48% is reported. In

our brief short experi-

### Tips and tricks for successful accomplishing this program

1. Adequate training as we have reported previously.<sup>18</sup>
2. Proper case selection according to the comfort level of surgeon.
3. Port placement and positioning.
4. Complex reconstruction like this should be attempted once achieved the proficiency in upper urinary tract reconstruction.

Based on data so far postoperative outcomes of robotic assisted augmentation are encouraging and have shown safety similar to open procedures, and outcomes at least equivalent and/or better. Accumulating data have consistently shown that postoperative analgesia requirements and overall hospital stay are decreased. However, operative durations are significantly longer than their open counterparts, but this is decreasing as experience accumulates. For pediatric urologist with experience in minimal invasive surgery the robotic assistance may be an additional option to offer for treating patients requiring complex lower urinary tract reconstruction.

Larger single-institution case series and comparative studies with the open approach will further evaluate the additional benefits of Robotic assisted laparoscopic surgery for lower urinary tract reconstruction in pediatric urology.

### References

1. Bramble FJ. The treatment of adult enuresis and urge incontinence by enterocystoplasty. *Br J Urol* 1982;54:693-6.
2. Mundy AR, Stephenson TP. 'Calm' ileocystoplasty for the treatment of refractory urge incontinence. *Br J Urol* 1985;57:641-6.
3. Baker LA, Docimo SG, Surer I, et al. A multi-institutional analysis of laparoscopic orchidopexy. *BJU Int* 2001;87:484-489.
4. Elliot SP, Meng MV, Anwar HP, et al. Complete laparoscopic ileal cystoplasty. *Urology* 2002;59:939-943.
5. Lorenzo AJ, Cerveira J, Farhat WA. Pediatric Laparoscopic ileal cystoplasty: Complete intracorporeal surgical technique. *urology*.2007;69-977-981.
6. Casale P, Feng WC, Grady RW, et al. Intracorporeal laparoscopic appendicovesicostomy; A case report of a novel approach. *J Urol* 2004 ;171;1899.
7. Hsu THS, Shortliffe LD. Laparoscopic Mitrofanoff appendicovesicostomy. *Urology* 2004;64,802-804.
8. Pedraa R, Weiser A, Franco I, Laparoscopic appendicovesicostomy (Mitrofanoff procedure) in a child using the da Vinci Surgical system. *J Urol*.2004; 171; 1652-1653.
9. Elliot S P, Meng M V, Anwar H P, et al Complete laparoscopic ileal cystoplasty. *Urology* 2002; 59.939-943.
10. Passerotti CC, Nguyen HT, Lais A, Dunning P, Harreli B, Estrada C et al. Robot-assisted laparoscopic ileal bladder augmentation: Defining techniques and potential pitfalls. *Journal of Endourology* 2008 (22),(2);355-360.
11. Gundeti MS, Eng MK, Reynolds S, Zagaja GP. Pediatric robotic-assisted laparoscopic augmentation ileocystoplasty and Mitrofanoff appendicovesicostomy: complete intracorporeal-initial case report. *Urology*;2008,72(5);1144-1147.
12. Gundeti M S, Acharya S S, Zagaja GP, The University of Chicago technique of complete intracorporeal pediatric robotic-assisted laparoscopic augmentation ileocystoplasty and Mitrofanoff appendicovesicostomy. *Journal of Robotic Surgery*;2009 (3),(2);89-93.
13. Gundeti MS, Acharya SS, Zagaja GP, Shalhav AL. Pediatric robotic-assisted laparoscopic augmentation ileocystoplasty and Mitrofanoff appendicovesicostomy (RALIMA): feasibility of initial experience with the University of Chicago technique. *BJU Int*. 2011 Mar;107(6):962-9.
14. Wille MA, Zagaja GP, Shalhav AL, Gundeti MS. Continence outcomes in patients undergoing robotic assisted laparoscopic mitrofanoff appendicovesicostomy. *J Urol*. 2011 Apr;185(4):1438-43.
15. Kispal Z, Balogh D, Erdei O, Kehl D, Juhas, Vastyan AM et al. Complications after bladder augmentation or substitution in children: a prospective study of 86 patients. *BJU Int*.2010,(108);282-289.
16. Behan JW, Kim SS, Dorey F, De Filippo RE, Chang AY, Hardy BE, Koh CJ- Human capital gains associated with robotic assisted laparoscopic pyeloplasty in children compared to open pyeloplasty. *J Urol* 2011;186 (4);1663-1667.
17. Rowe C K, Pierce M W, Tecci K C, Houck C S, Mandell J, Retik A B et al -A comparative direct cost analysis of pediatric urologic robot-assisted laparoscopic versus open surgery: could robot-assisted surgery be less expensive? *J of Endourology* [epub ahead of print].
18. Orvieto MA, Large M, Gundeti MS-Robotic paediatric urology . *BJU Int* 2012;110(10):2-13.

# III. MINIMALLY INVASIVE BLADDER OUTLET PROCEDURES

## Laparoscopic-Assisted Autologous Fascia Sling for Urinary Incontinence

Dr. Jorge A. Garcia Andrade, Chief of Urology Service, Baca Ortiz Hospital, Quito, Ecuador  
Pediatric Urologist, De los Valles Hospital, Metropolitano Hospital, Millennium Hospital

### Introduction

When managing urinary incontinence caused by the incompetence of the external urethral sphincter in patients with neurogenic bladder, the variety of techniques applied to the bladder neck to offer scheduled continence enjoy benefits and suffer complications at the same time. This has become a real dilemma in Pediatric Urology. The medical problem of the low resistance of the neck to the output of urine adds to the patient's psychological distress and stigmatization by society.

The attempt to improve the conditions for reservoir and continence, without affecting the upper urinary tract, has gained ground in recent years, especially by handling incontinence by bladder neck sling using rectus fascia.

In order to adequately address and correct the incompetence of the external urethral sphincter in patients with neurogenic bladder, techniques have been described and practiced over several decades with extra- and intravesical approaches to the bladder neck. Techniques include: artificial urinary sphincter placement; neck strip tubularization; placement of prosthetic or fascia slings; peri-urethral injection of bulking agents; and, as a last option, urinary diversion with a bladder neck closure and creation of a catheterizable channel (Mitrofanoff or Monti). Apparently the use of artificial urinary sphincter aimed to be the best option due to the excellent continence results. However many complications have been reported throughout the years with the use of the device, including fault-predominant surgical revisions, erosions and infections in the urethra. Regarding bulking agents, the main drawback is the length [duration of benefit], migration, and lack of acceptance by the host.<sup>1,4,5</sup>

The bladder neck reconstruction with tubularization causing urethral elongation, including the Young-Dees-Leadbetter and Kropp techniques, still remains a good treatment option for improving incontinence.

In recent years the sling with autologous rectus fascia has gained ground with acceptable continence in girls and a low complication rate. However complications are not uncommon by conventional open surgery: urethral injuries; creation of iatrogenic urethral vaginal fistula; improper passing of the sling by the posterior face of the bladder neck with obstruction of the ureter or deferent duct in males; improper sling calibration with persistent incontinence; and heavy bleeding in the lateral neck dissection.

Since 2009, we have modified the classical open technique, incorporating dissection and construction of the sling completely laparoscopically, other than harvesting a strip of autologous fascia and accurately calibrating the neck under laparoscopic and cystoscopic control. Our results are satisfactory, with good continence in patients of both sexes. It seems that the free graft recommended by Snodgrass<sup>8</sup> works best as an option to calibrate the upper portion of the urethra and bladder neck, and it is ideally suited for our laparoscopic/endo-scope technique.<sup>1,2,8</sup>

This technique offers many advantages over conventional surgery - clear view of the pelvic cavity, the ureters and deferent ducts at their

entry posterior to the bladder, as well as total dissection under direct visualization of the bladder neck, urethra, and the anterior vaginal or rectal wall. Controlled passage of the fascia sling (avoiding obstruction of the ureters or a deferent duct and avoiding fistula from an unnoticed pass through the vagina or rectum) is required.<sup>1,2,3</sup>

### Technique

Cystoscopy is performed under general anesthesia to assess the urethra, bladder neck and bladder. The camera port is placed in the umbilicus. For the instruments, two 5 or 3 mm ports are placed to the sides at the level of the anterior axillary line. An optional fourth working port is placed at the mid-clavicle line in order for the assistant to better [manipulate] the bladder, vagina or rectum at the appropriate time. The first surgical step is to dissect the front of the bladder, separating the anterior parietal peritoneum to reach the level of the symphysis pubis. At this time the bladder neck is released with fine dissection from the space of Retzius while avoiding possible bleeding. If bleeding occurs, you have to use monopolar coagulation or the harmonic scalpel. After this dissection you are able to see the proximal urethra (anterior and lateral aspects). The next step is to anchor the bladder dome to the anterior abdominal wall with a transfixing stitch of Vicryl™ (polyglactin 910) 2/0.

With this move we can dissect and have a perfect view of the posterior bladder, the ureters, the anterior rectal wall, and the uterus/vagina in women or the deferent ducts in men. Once we have dissected the bladder neck, we proceed to guide a penrose drain through the space.. By mini- incision, we develop an anterior rectus fascial strip and we pass it as a free graft or pedicle to the abdominal cavity, sutured at its free end to the drain guide. It is wrapped around the bladder neck at the lowest possible level. The sling is sutured to the anterior neck using non-absorbable stitches Ethibond Excel™ Polyester Suture 3/0). It is adjusted under cystoscopic vision; we can appreciate how the fascia strip compresses and functionally occludes the neck yet allows the passage of an 8 Fr probe and future intermittent catheterization. The final step is to attach the strip to the pubic periosteum in order to create a suspension and bladder neck angulation. An 8 Fr. Nelaton catheter should be left into the urethra for 10 days after surgery is performed.<sup>1</sup>

### Our Experience

We intervened by laparoscopy in 8 patients between 3 and 13 years of age carrying a diagnosis of neurogenic bladder secondary to myelomeningocele. All were characterized by external urethral sphincter incompetence with LPP between 20 to 25 cm as preoperative urodynamic measurements. Three cases were males. In 4 patients the wrap was applied using a free graft of rectus fascia, while a pedicled fascial segment [left attached at harvest site] was applied in the remaining 4 patients.

(continued on next page)

## Laparoscopic-Assisted Autologous Fascia Sling

(continued from previous page)

The 8 patients were monitored anywhere from 8 months to 3 years of follow-up. Currently, they are all treated with daily catheterization. Six out of the eight patients (3 male/3 female) have periods of dryness between 3 to 4 hours. Unfortunately one case of a 5 year old girl was unsuccessful. In this patient we used pedicled fascia. We assume that the wrap of fascia was opened spontaneously during early post-surgery days, and incontinence reappeared.

### Summary

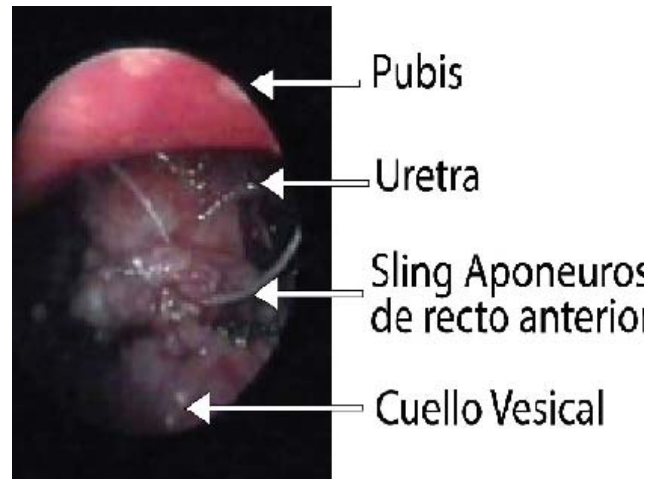
In our opinion, the use and vision by means of laparoscopy or robotics in areas of the bladder neck and proximal urethra is something that conventional/open surgery does not have. We can deal with minimal bleeding in the Retzius' space, and we can separate the vagina, ureters and vas deferens at the bladder floor carefully and under clear control. The most important step is to move and anchor the sling under direct vision at the level of the bladder neck and proximal urethra. We do this under cystoscopic vision, filling the bladder with a saline solution and appreciating the degree of constriction and resistance at the bladder neck. If we see a good functional closure of the neck, we proceed to anchor the fascia strip to the pubic periosteum in order to suspend and angulate the cervical area.

We believe that this technique should be encouraged in children of both genders when characterized as sphincter deficiency with LPP less than 30 cm of water. In cases of patients with hyperactive bladders that demonstrate severe detrusor overactivity and associated low bladder capacity, it is advisable to carry out a complementary bladder enlargement procedure.

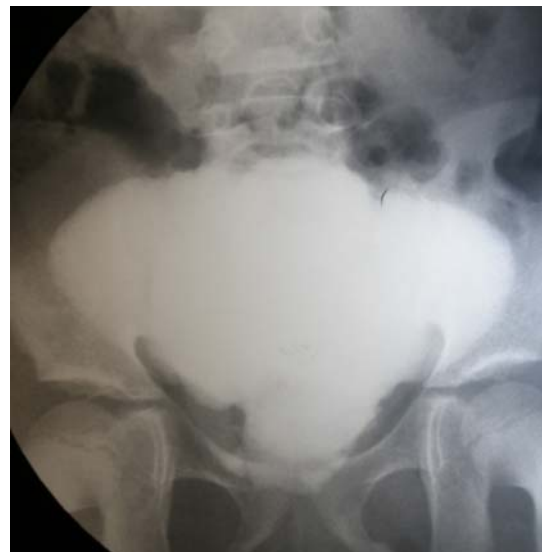This technique is useful for urologists with expertise in advanced minimal access procedures, especially in the pelvic cavity, taking into account that the area of dissection involves risk to structures such as the Retzius space, iliac and femoral vessels, ureters, vagina and vas deferens, all of which should be carefully identified and spared.

### References

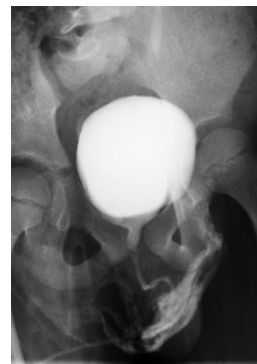
1. García Andrade J.: *Our experience in managing patients with neurogenic bladder and anal incontinence associated.* Disorders lavatories. 1st Edition, Ed Pedagogical Freire. Ecuador, 90-92. 2010
2. García Andrade J.: *Laparoscopic bladder neck reconstruction with sling fascia in patients with neurogenic bladder.* Conference presented in CIPESUR congress. Viña del Mar, Chile. Nov. 2009
3. Ferrer FA.; Tadros YE.; Gearhart J.: *Modified Young-Dees-Leadbetter bladder neck reconstruction: new concepts about old ideas.* Urology.58:791-796. 2001.
4. Gonzalez R.; Merino F.; Vaughn M.: *Long-term results of the artificial urinary sphincter in male patients with neurogenic bladder.* Journal Urology 54: 769-770. 1995.
5. Bomalaski M.; Koo H.; Blom D.: *Injectable bulking agents in the treatment of urinary incontinence.* In: Gerhart J.; Rink R.; Mouriquand P.: (eds.) *Pediatric Urology Saunders.* Philadelphia, pag. 108, 2001.
6. Rink R.; Mitchell M.: *Bladder neck/urethral reconstruction in the neuropathic bladder.* Urology. 105-106. 1987.
7. Kropp K.: *Bladder neck reconstruction in children.* Urology Clin. North Am. 26: 661-172. 1999.
8. Snodgrass W.; Adams R.: *Bladder neck sling and appendicovesicostomy without augmentation for neurogenic Incontinence in children.* Journal of Pediatric Urology. 3:1, 60. 2007



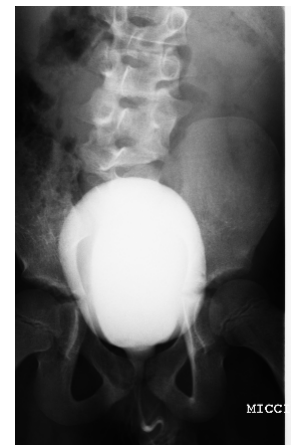Laparoscopic view of bladder neck reconstruction with autologous fascia sling in 5 years old boy with neurogenic bladder.



9-year old girl after bladder neck reconstruction with fascia sling and augmentation with ileum. This patient has 6 hour dry periods prior to each catheterization. In the cystogram, appreciate the sling constriction on the neck of the bladder.



5-year old boy with neurogenic bladder prior to laparoscopic sling reconstruction. Appreciate the bladder neck insufficiency and urine escape.



The same patient 3 years after the laparoscopic sling reconstruction. Appreciate the new bladder neck area.

# Robotic Assisted Laparoscopic Sling Procedure for Bladder Outlet Incompetence

Marc Cendron, MD and Hiep Nguyen, MD

Children's Hospital Boston, Department of Urology, Boston Massachusetts

Bladder outlet incompetence is a rather rare occurrence in the pediatric age group but will be found in patients with neurogenic bladder as well as patients with bladder exstrophy-epispadias complex. The diagnosis is usually achieved by voiding cystourethrogram and urodynamic confirmation. Findings at the time of VCUg will include wide bladder neck with reduced bladder capacity (Fig 1). On urodynamic findings, low intravesical pressures with low leak point pressures and, again, reduced bladder capacity will be documented. There are no reliable medical treatments for the condition. Options for management include: 1. Endoscopic injection of bulking agents at the level of the bladder neck/proximal urethra, 2. Sling procedures, 3. Surgical bladder neck reconstruction (cervicoplasty), and 4. Placement of an artificial urinary sphincter.

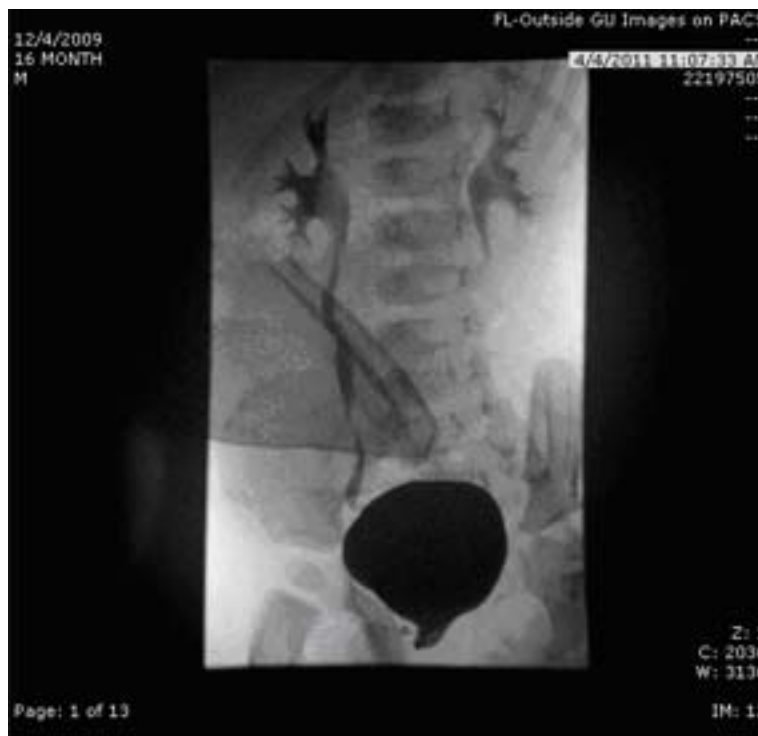

Figure 1: Wide open bladder neck as demonstrated by VCUG in a patient with peno-pubic epispadias.

The advantage of the sling procedure is its relative straightforward application. Several small series have documented its good efficacy and low complication rate.<sup>1-4</sup> Several materials for the sling procedure have been described. They include anterior rectus fascia, SIS, and processed pericardium.<sup>5</sup>

Sling procedures in children are usually carried out as an open surgical procedure and may be done in conjunction with bladder augmentation and creation of a catheterizable urinary stoma. In males, a sling procedure is often rendered more difficult because of the complexity of dissecting the bladder neck. Use of the Lottmann retrovesical dissection technique has helped access the bladder neck in males.<sup>6</sup> However, laparoscopic techniques have markedly improved surgical access to the anatomic structures deep in the pelvis. Additionally, the

robotic approach has further enhanced the ability to access both the anterior and posterior aspect of the bladder neck especially in males. Further advantages of the robotic procedure over the laparoscopic approach include improved mobility and increased range of motion of the instrument as well as better view of the deep pelvic structures. Cost of the robot is clearly one of the disadvantages.

Sling procedures should be considered in males with epispadias/exstrophy complex as well as those patients with neurogenic bladder and bladder outlet incompetence. It is especially well suited for patients with the more simple forms of epispadias, especially the penile or glanular epispadias who may have some degree of proximal urethral and bladder neck incompetence.

A small series of 4 patients was studied. They were evaluated between 2003 and 2010. Ages of these patients, who were all male, went from 5 to 12 years. Three patients had epispadias and one had a neurogenic bladder secondary to spina bifida. All patients underwent a VCUG and a full urodynamic study. All patients showed a bladder capacity <120 cc and a leak point pressure of <15cm H<sub>2</sub>O. Preoperative cystoscopy was carried out to document the patulousness of the bladder neck. None of the patients had any prior bladder neck procedures or injections. Two patients had been on anticholinergic medication with modest improvement in the incontinence. All of them had significant leakage, both at rest and with straining.

## Surgical Technique and Postoperative Regimen

With the patient in the extended dorsal lithotomy position, after cystoscopic evaluation, the robot is positioned between the patient's legs (Fig 2). The camera port is inserted at the umbilicus. A cystoscope is available at all times during the procedure. Two or three lateral mid abdominal ports are placed in both right and left lower quadrants. A 12 French Foley catheter is in place through the urethra and in the bladder except for the times when cystoscopy is carried out.

(continued on next page)

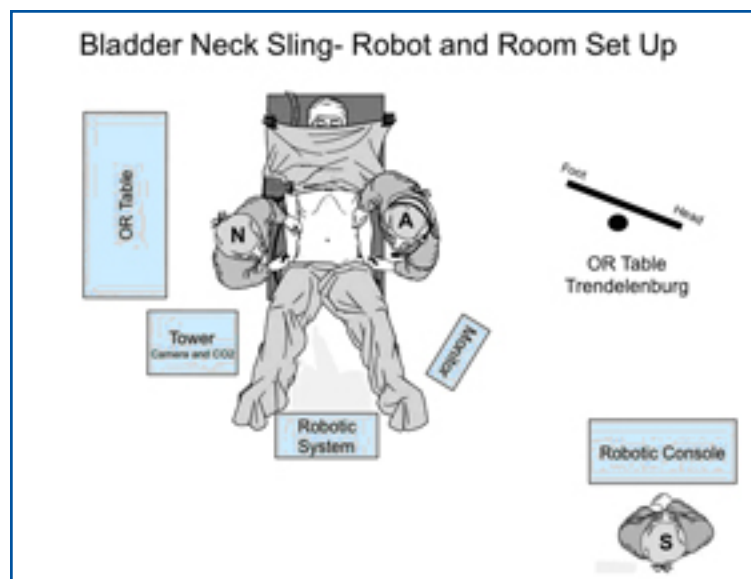


Figure 2: Positioning of the robot for RALS-Sling procedure

## Laparoscopic Sling Procedure *(continued from previous page)*

A bladder stitch is placed through the abdominal wall so as to elevate the bladder. An inferior retrovesical dissection is done and is carried out until the seminal vesicles are identified. Lateral dissection of the endopelvic fascia is then achieved. A supravescical anterior dissection of the bladder neck is then made. The bladder neck is then mobilized, with incision of the endopelvic fascia laterally, usually from below.

A surgical umbilical tape is placed around the bladder neck, and cystoscopy is used to ensure proper positioning and to ensure that the bladder neck and proximal urethra are intact. The sling material is then sutured to the umbilical tape. SIS was used in all cases. The sling is then placed around the bladder neck in a cinch wrap technique (Fig 3). Two small suprapubic incisions are made and the anterior rectus fascia is accessed just above the pubic symphysis. Two small puncture incisions are made through the rectus fascia on either side of the midline, and each end of the sling is brought through a fascial incision.

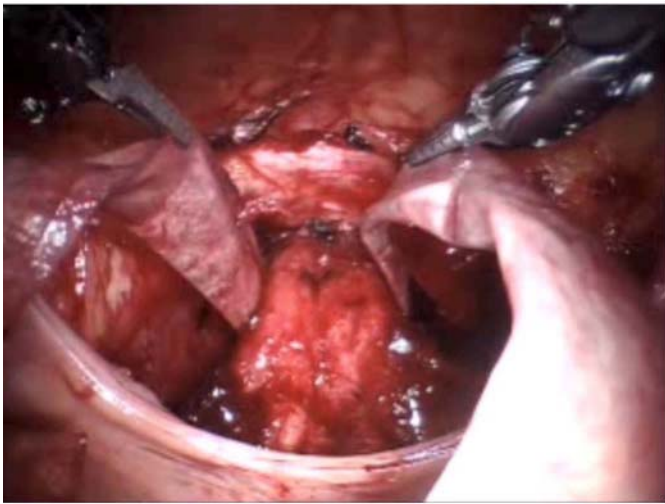


Figure 3: Placement of the SIS sling around the bladder neck

The sling is cinched up into position with upward traction (Fig 4). Cystoscopic evaluation of the bladder neck documents the elevation and coaptation of the bladder neck. The sling is then sutured in position on the anterior abdominal wall and the incisions are closed. A suprapubic tube is inserted. A Foley catheter is left in place for 24-48 hours. The suprapubic tube is left indwelling for 2-4 weeks. At 3-4 weeks a cystogram is carried out. Suprapubic clamping regimen for at least 2 weeks is then achieved with a suprapubic tube left in place until good documentation of adequate voiding and complete emptying. Once the voiding pattern has been established and documented, the suprapubic tube can be removed. The patient is then placed on a strict voiding schedule.

Potential complications of the procedure are injuries to the bladder neck and to the surrounding structures. In general, the robotic procedure provides sufficient visualization of the pelvic structures that these complications should be very rare. We did not experience any of these issues in our series. Other potential complications include urinary tract infections and urinary retention, which we did not experience in our patients. One of our patients did experience one symptomatic urinary tract infection 2 months postoperatively. Of the 4 patients

studied, 3 patients had significant improvements in the day incontinence with dry intervals for 2-3 hours. One patient is dry at night. One patient has dry intervals for at most 1 to 1.5 hours and has been on anticholinergic medications for overactivity. All patients have some degree of stress-induced leakage when they strain or increase their intra-abdominal pressure. On urodynamic testing, bladder capacity and leak point pressure were increased in all cases.

### Summary

The robotic-assisted laparoscopic sling procedure is a relatively straightforward procedure from the technical standpoint. It appears to be quite safe. The advantage of the sling procedure is that it does not preclude subsequent procedures on the bladder neck. Proper patient selection is essential. The procedure provides a good option for the management of bladder neck incompetence in patients with either epispadias/exstrophy complex or neurogenic bladder. Clearly, the robotic aspect of the procedure entails an increased technical complexity and cost but the advantages are its ability to provide good access to the bladder neck, and therefore it allows for a safer dissection and placement of the sling. Larger, long-term studies are certainly needed to validate this technique.

### References

1. Barthold JS, Rodriguez AL et al. Results of rectus fascia sling wrap procedures for the treatment of neurogenic sphincter incontinence. *J Urol* 161, 1999, pp272-274.
2. Austin PF, Westney OL et al. Advantages of rectus fascial sling for urinary incontinence in children with neuropathic bladder. *J Urol* 165 (2001), pp.2369-2372.
3. Castellan M, Gosalbez R et al. Bladder neck sling for the treatment of Neurogenic incontinence in children with augmentation cytoplasty: long-term follow-up. *J Urol*.173 2005, pp 2128-2131.
4. Snodgrass WT, Elmore J et al. Bladder neck sling and appendicovesicostomy without augmentation for neurogenic incontinence in children. *J Urol* 177, 2007, pp1510-1515;
5. Chrzan R, Dik P et al. Sling suspension of the bladder neck for pediatric urinary incontinence. *J Ped Urol*, 5, 2007, pp. 82-85.
6. Lottmann H, Traxer O et al. Posterior approach to the bladder for implantation of the 800 AMS AUS in children and adolescents. *Ann Urol (Paris)* 33, 1999, (5) 357-363.

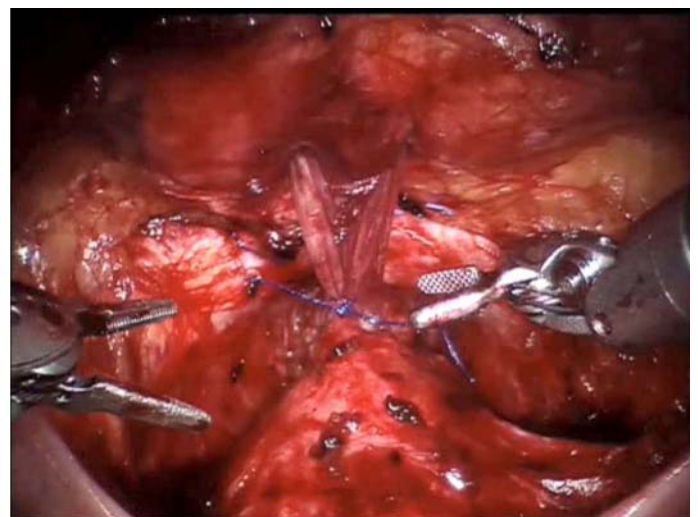


Figure 4: anterior view of the SIS sling cinching up the bladder neck. Note the two strands of SIS passing through the anterior rectus sheath

# Robotic-Assisted Bladder Neck Reconstruction

Aditya Bagrodia, MD and Patricio Gargollo, MD  
Department of Urology, Division of Pediatric Urology, Children's Medical Center  
University of Texas Southwestern Medical Center, Dallas, Texas

## Introduction

Given the variability and spectrum of bladder structure, function, and compliance (small capacity/hyperreflexic to myogenic failure/acontractile with increased capacity) and also in bladder neck/external sphincter physiology (hypertonic to extremely low detrusor and stress leak point pressures), patients may require bladder neck procedures to obtain urinary continence.<sup>1-2</sup> Options include injection of bulking agents around the bladder neck, placement of artificial urinary sphincter (AUS), bladder neck reconstruction, and fascial sling procedures.<sup>3</sup> Snodgrass and colleagues reported successful outcomes in patients receiving bladder neck sling (BNS) and appendicovesicostomy (APV) without augmentation, with only 1/30 (3.3%) patients ultimately requiring enterocystoplasty for symptomatic hyperreflexia and compliance loss.<sup>4</sup> Further, the same authors demonstrated that at a mean of 39 months, urodynamic patterns remained stable or improved in comparison to pre-operative urodynamic studies for patients receiving sling/APV without augmentation. No new cases of hydronephrosis, bladder trabeculation, or reflux were identified in that cohort.<sup>5</sup>

In efforts to enhance continence rates, Snodgrass and colleagues began performing Leadbetter-Mitchell bladder neck reconstruction (BNR) in addition to fascial sling. The cohort receiving BNR plus sling had a 94% complete continence rate compared to 46% that underwent sling alone.<sup>6</sup> At our institution, bladder neck surgery is performed for detrusor leak point pressure <50 cm H<sub>2</sub>O or a history of stress urinary incontinence despite clean intermittent catheterization and maximal anticholinergic therapy.

The benefits of minimally invasive surgery (MIS) include shorter hospital durations, decreased analgesic requirements, and faster convalescence. We began performing robotic-assisted APV with BNR/BNS such that the advantages of MIS may be realized in the patient population with neurogenic bladder and sphincteric incompetence.

## Inclusion Criteria

All patients received a pre-operative urodynamic study (UDS) once they were on maximal anticholinergic therapy (the greater of 0.2mg/kg or 5mg QID of oxybutynin). Patients were designated as having sphincteric incontinence and counseled to receive APV with BNR/BNS if they had detrusor leak point pressure (DLPP) <50 cm H<sub>2</sub>O or a history of stress urinary incontinence despite clean intermittent catheterization and maximal anticholinergic therapy.

## Technique

Pneumoperitoneum is established using a Veress needle. The working ports are secured to the patient's skin with TroGARD® (Conmed Corporation 310 Broad St. Utica, NY). Once all ports are secured, the robot (da Vinci Surgical System, Intuitive Surgical, Inc., Sunnyvale, CA) is docked.

On the back table, two 10-French subclavian line tunneling devices, cut to 2.5 centimeters, were attached with 3-0 polydioxanone (PDS) suture to a 10 centimeter x 1 centimeter strip of Tutoplast cadaveric fascia (IOP, Inc, Costa Mesa, CA), which would serve to create the sling.

An inverted V-shaped incision was made at the umbilicus, ultimately serving as the future skin flap to bring to the

appendicovesicostomy, and the 12-mm robotic camera was placed after Veress needle insufflation. Under direct visualization, two 8-mm robotic ports were placed: the first in the right midclavicular line slightly superior to the camera port and the second in the left midclavicular line just inferior to the umbilical site. A 12-mm assist port was placed between the left arm and the working camera port. A 12-mm trocar was used in order to accommodate suture needles and Lapra-Ty (absorbable suture clips).

After the robot is docked, a crescent-shaped incision was made posterior to the bladder in order to drop the rectum in males or vagina in females. Distal to the seminal vesicles (in boys), the prepared sling was passed ventrally on both sides of the bladder neck into the space of Retzius using the tunnelers (Fig 1-3). The bladder was dropped anteriorly, and the suspensory puboprostatic ligaments were divided using monopolar cautery. A 2-0 polyglactin dorsal vein stitch was placed prior to cutting down to the catheter and unroofing the proximal urethra and bladder neck to the level of the inter-ureteric ridge (Fig 4-6). The Foley catheter was exchanged for a 5-French feeding tube, and the urethra was retubularized in two layers with a running simple suture of 5-0 PDS (polydioxanone) followed by 4-0 PDS (Fig 6). Bladder integrity was ascertained by injecting the bladder with saline.

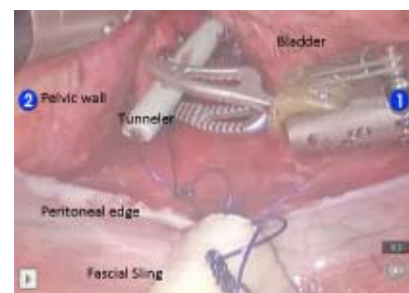

Figure 1: Posterior view of bladder. Tunnelers with fascial sling attached with PDS suture is passed anteriorly into Space of Retzius.

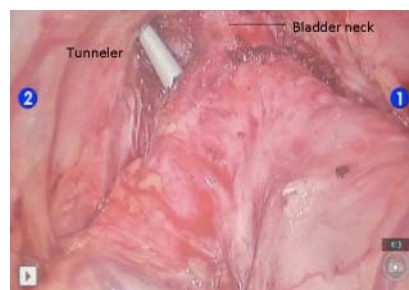


Figure 2: Anterior view of bladder. Tunnelers are retrieved.

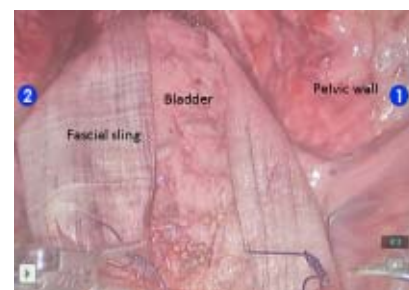


Figure 3: Anterior view of bladder. Both tunnelers are retrieved anteriorly as the sling engulfs the posterior bladder neck

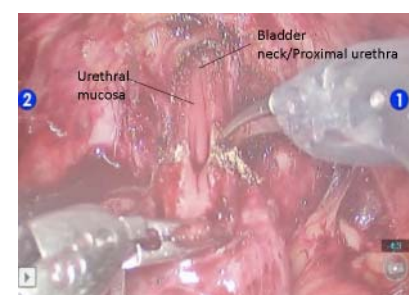


Figure 4: Beginning of Leadbetter/Mitchell bladder neck reconstruction

(continued on next page)



## Bladder Neck *(continued from previous page)*

Following the Leadbetter-Mitchell BNR, the tunneling devices were identified by dissecting lateral to the urethra. The sling was tightly wrapped 360 degrees and attached to the pubic bone using six screws from a hernia tacker (Fig 7). Appendicovesicostomy is then created as previously described.<sup>7</sup>

We reported our initial feasibility series of Robotic-assisted bladder neck reconstruction, sling, and appendicovesicostomy in 2011.<sup>7</sup> Thus far, nine cases have been completed robotically, with one conversion. One patient required conversion to open surgery for marginal appendiceal mesentery and required creation of Monti channel. No other perioperative complications were reported. Two patients developed de novo reflux that responded to dose escalation of anticholinergics. All are completely dry and able to catheterize their APV easily.

### Summary: A few personal considerations

Longer term data with more patients is required before any definitive conclusions can be drawn from our data. The operation is lengthy and technically challenging, and operator endurance and fatigue are real concerns. The entire operative staff must be willing to learn and work together as a team, particularly when performing new procedures with unforeseen hurdles. I assisted on numerous open

appendicovesicostomy with bladder neck reconstruction and sling procedures prior to embarking on the robotic approach; this is integral. Novel maneuvers, such as utilizing dorsal venous stitches and subclavian tunnelers, must be employed for success and will continue to arise with experience.

### References

1. McGuire EJ, Cespedes RD, O'Connell HE. Leak-point pressures. *Urol Clin North Am.* May 1996;23(2):253-262.
2. Wan J, McGuire EJ, Bloom DA, Ritchey ML. Stress leak point pressure: a diagnostic tool for incontinent children. *J Urol.* Aug 1993;150(2 Pt 2):700-702.
3. Kryger JV, Gonzalez R, Barthold JS. Surgical management of urinary incontinence in children with neurogenic sphincteric incompetence. *J Urol.* Jan 2000;163(1):256-263.
4. Snodgrass WT, Elmore J, Adams R. Bladder neck sling and appendicovesicostomy without augmentation for neurogenic incontinence in children. *J Urol.* Apr 2007;177(4):1510-1514; discussion 1515.
5. Snodgrass W, Barber T, Cost N. Detrusor compliance changes after bladder neck sling without augmentation in children with neurogenic urinary incontinence. *J Urol.* Jun;183(6):2361-2366.
6. Snodgrass WT, Barber T. Comparison of Bladder Outlet Procedures without Augmentation in Children with Neurogenic Incontinence. *J Urol.* 2010; In press
7. Bagrodia A, Gargollo P. Robot-assisted bladder neck reconstruction, bladder neck sling, and appendicovesicostomy in children: description of technique and initial results. *J Endourol.* Aug;25(8):1299-1305.

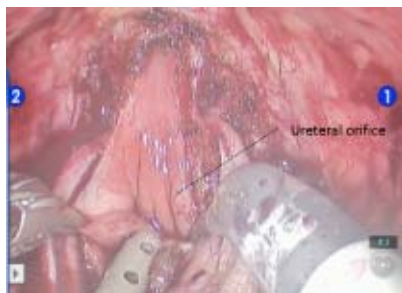

Figure 5: Ureteral orifices are identified after injection of indigo carmine

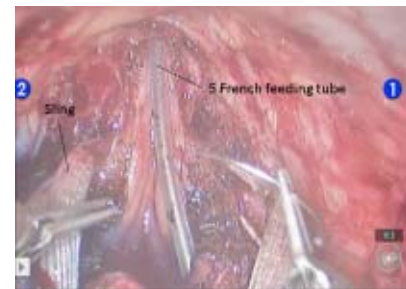


Figure 6: Retubularization of bladder neck over 5-French feeding tube.

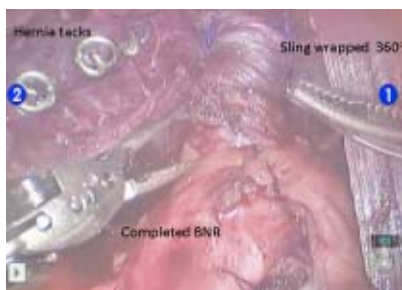


Figure 7: Fascial sling is wrapped 360 degrees and tacked to pubic bone

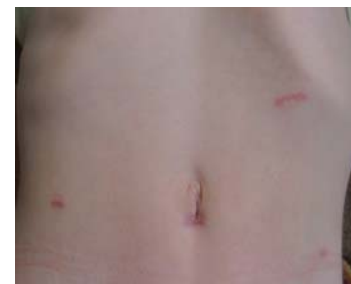

Figure 8: Representative 6 week post-operative patient

# Laparoscopic Approach or Artificial Sphincter for Urinary Incontinence

Dr. J. Moldes, Dr. R. Vagni, Dr. E. Ormaechea, Dr. S. Callello, Dr. F. de Badiola  
Service of Pediatric Surgery, Section of Pediatric Urology.  
Hospital Italiano de Buenos Aires, Argentina

The placement of an artificial urinary sphincter (AUS) is the first option for neurogenic sphincter incompetence treatment, with many on spontaneous voiding.<sup>1,2</sup> The most commonly used approach is a Pfannenstiel or a midline sub-umbilical incision, since the bladder neck is the location of choice in children.

This intervention requires a careful dissection of the bladder neck to place the sphincter cuff, taking care with surrounding structures, especially the rectum in males and the vagina in females. This maneuver may be done with an anterior approach and blind dissection of the posterior wall of the sphincter. Another option is the posterior approach, dissecting along the posterior face of the bladder and the bladder neck.<sup>1,3</sup> The potential complications of blunt and blind dissection of the anterior or retropubic dissection will be prevented by the posterior approach.

We choose to use laparoscopy for the insertion of an artificial sphincter to reduce the size of the incision and especially to have a better view and delicate dissection of the posterior face of the bladder neck.

## Surgical Technique

At the surgery a 10 mm port was placed at the umbilicus for the optic and a 5 mm trocar in each iliac fossa. A stitch was placed through the abdominal wall into the dome of the bladder for retraction. The peritoneum at Douglas' sac was opened with hook cautery. After a complete laparoscopic exposure of the posterior and lateral spaces of the bladder neck, we complete the distal dissection beyond the Foley balloon. A small Pfannenstiel incision is made to complete the dissection

all around the bladder neck and to place the cuff and the sphincter balloon.

## Our Experience

Our first 10 patients operated by laparoscopy were patients with neurogenic [sphincteric] incompetence, with an average age of 8.5 years (range: 3 - 20) and with follow-up more than 5 years (range: 5 - 12). Average surgical time was 186 min (range: 150 - 230). One sphincter had to be removed 5 years after placement because of erosion,

and a new sphincter was placed at the urethra. In our experience, we have similar results with the open approach.<sup>1</sup>

The advantage of this technique is the comfortable and secure dissection of the bladder neck. This is because of the optical magnification, which allows a better recognition of structures, and because the length of the laparoscopic instruments provides an ergonomic approach to an otherwise uncomfortable line of dissection. The surgeon thus avoids a blind dissection of the posterior bladder neck, as made in the conventional approach, and avoids the possibility of damaging the vagina, rectum, seminal vesicles or vas deferens.

As a disadvantage, the laparoscopic access transforms a procedure generally performed completely extraperitoneal into a transperitoneal approach.

There are descriptions of placement of the AUS completely through laparoscopy in adults, but a small incision is always required.<sup>4-6</sup> We prefer to use the suprapubic incision to dissect the anterior and lateral walls of the bladder neck and to communicate this space with the posterior dissection by laparoscopy in females, post-pubertals and reoperations.

## Summary

We think this technique should be used in older patients, especially females, in order to perform a careful division of the surrounding structures. In younger patients the size of the incision required to place the sphincter is big enough to do the entire dissection, and the use of laparoscopy loses its benefits.

## References

1. Ruiz E, Puigdevall J, Moldes J, Lobos P, Boer M, Ithurralde J, Escalante J, de Badiola F. 14 years of experience with the artificial urinary sphincter in children and adolescents without spina bifida. *J Urol.* 2006;176:1821-5.
2. Kryger JV, González R, Barthold JS. Surgical management of urinary incontinence in children with neurogenic sphincteric incompetence. *J Urol.* 2000 Jan;163(1):256-63.
3. Lottmann H, Traxer O, Aigrain Y, Melin Y. Posterior approach to the bladder for implantation of the 800 AMS artificial sphincter in children and adolescents: techniques and results in eight patients. *Ann Urol.* 1999;33(5):357-63.
4. Gamé X, Bram R, Abu Anz S, Doumerc N, Guillotreau J, Malavaud B, Rischmann P. Laparoscopic insertion of artificial periprostatic urinary sphincter. *Urology.* 2009;73(2):442.e1-3.
5. Roupêt M, Misraï V, Vaessen C, Cardot V, Cour F, Richard F, Chartier-Kastler E. Laparoscopic approach for artificial urinary sphincter implantation in women with intrinsic sphincter deficiency incontinence: a single-centre preliminary experience. *Eur Urol.* 2010;57(3):499-504.
6. Mandron E, Bryckaert PE, Papatsoris AG. Laparoscopic artificial urinary sphincter implantation for female genuine stress urinary incontinence: technique and 4-year experience in 25 patients. *BJU Int.* 2010;106(8):1194-8.

**We choose to use laparoscopy for the insertion of an artificial sphincter to reduce the size of the incision and especially to have a better view and delicate dissection of the posterior face of the bladder neck.**

# IV. ROLE OF MINIMALLY INVASIVE TECHNIQUES IN THE MANAGEMENT OF DSD

## Minimally Invasive Approach for Disorders of Sex Development

Marcos Giannetti Machado

Division of Urology, University of São Paulo School of Medicine Hospital, São Paulo, SP, Brazil

The management of children born with disorders of sexual development (DSD) still remains challenging and has undergone major changes in recent years. The major change is the consensus that the rarity and complexity of these cases makes a multidisciplinary approach mandatory. Pediatricians, pediatric surgeons, urologists, gynecologists, endocrinologists, psychiatrist or psychologist, geneticist, specialized nurses and, above all, the parents, need to work together in order to achieve the best possible results. Patients should be treated preferably at a reference treatment center and no assignment of gender should be made without complete multidisciplinary agreement. [Gender assignment] has to be on an individual basis, including even cultural issues.

Other important change was related to nomenclature. The terms male pseudohermaphrodite, female pseudohermaphrodite and true hermaphrodite are no longer used. A new nomenclature removed the gender references, frequently controversial, and incorporated genetic etiology and descriptive terminology. The main DSD categories are now 46,XX DSD, 46,XY DSD and sex chromosome DSD (45,X Turner Syndrome and variants, 47,XXY Klinefelter Syndrome and variants, 45,X/46,XY mixed gonadal dysgenesis, 46,XX/46,XY chimeric ovotesticular DSD).<sup>1</sup>

Another concept that has been questioned, but not changed, is related to early corrective surgical procedures, especially related to gender assignment and appropriate genital surgery in infancy. Some authors, backed by patient and parents support groups, advocate that premature genital procedures can be mutilating and should be postponed until formal consent of the patient could be granted. However, gender uncertainty is disturbing and stressful for most parents, and early diagnosis and proper treatment, including surgery, could promote better quality of life and less psychological harm for the patients and their families.<sup>2</sup>

Even though the preferred gender assignment is not always clear, a complete evaluation of endocrine function, karyotype, potential for fertility, genital appearance, internal organs anatomy, risk for gonadal malignancy, wishes of the parents, and social cultural environmental issues can lead to a well-balanced decision.

Surgical procedures play a major role in order to adequate the genital area and the internal organs to the assigned gender. Treatment includes not only cosmetic and functional repair of the external genitalia, but also removal of all normal structures contrary to the gender assigned as well as gonads that are either dysgenetic, nonfunctional or malignant or of increased malignant potential.

From this surgical scenario, laparoscopy emerged as a valuable tool to be used in most cases, since it gives an excellent view of the pelvic structures, including the genital organs, allowing safe identification and removal of undesirable components even in very young children<sup>3</sup>.

The classical advantages of laparoscopy compared to open surgery are present and include the elimination of a sizeable laparotomy

incision, resulting in less discomfort after surgery, less need for analgesia, and a shorter hospital stay, convalescence and return to normal activities. Other advantages include magnification, excellent visibility and illumination, and less venous oozing because of the pressure effect of the pneumoperitoneum. One of the main advantages of this method is the lack of scars, a very important issue for these patients, who need reaffirmation of their body image and self-esteem.<sup>4</sup>

The main applications of therapeutic laparoscopy in DSD patients according to the nature of the DSD are summarized in table 1.

### 46,XX DSD

These patients undergo virilization due to exposure to androgens in fetal life. The major cause is congenital adrenal hyperplasia (CAH). Female ductal structures and ovaries are always present. Usually the vaginal cavity is connected to the posterior wall of the urethra with variable distance. It is important to assess the level of confluence for adequate surgical planning. Pelvic ultrasound scan and magnetic resonance imaging are very useful to elucidate the internal anatomy.<sup>5</sup>

Cosmetic repair of genitalia by a reduction clitoroplasty and separation of the vagina from the urethra are the surgical targets, since the vast majority of these patients are assigned females, and laparoscopy is not needed. The appropriate age to perform these procedures has been questioned as mentioned before.<sup>6</sup>

However, there are very uncommon cases raised as males that will need masculinization of the genitalia and laparoscopic removal of the female gonads (ovaries) and müllerian derivatives (uterus, tubes, vagina). Laparoscopy is excellent for the removal of the uterus and vaginal component of the urogenital sinus in patients with male social sex. Complementary perineal resection of inferior vaginal segment of urogenital sinus was required in some cases.<sup>7</sup>

### 46,XY DSD

Despite the 46,XY karyotype, these patients have an incomplete masculinization of the external genitalia caused by inadequate testosterone production (gonadal dysgenesis), failure to its conversion to dihydrotestosterone (5 alpha-reductase deficiency) or androgen insensitivity syndrome, that can be partial (PAIS) or complete (CAIS). In these cases, gender assignment can be very complicated.

Historically many of these severely undervirilized genetic males were raised and surgically assigned females, because it was the easiest surgical approach. However, most of them, if untreated, showed a strong tendency to assume male gender at puberty. If female gender is assigned, testes can be removed through an inguinoscrotal approach if they are palpable or by laparoscopy if intra-abdominal. If male gender is assigned, normal testes can be relocated to the scrotum through an inguinoscrotal approach if they are palpable or by laparoscopy in one or two stages if intra-abdominal. The müllerian structures (uterus, tubes and vaginal component of urogenital sinus) can be removed by laparoscopy. Dysgenetic

*(continued on next page)*

**DSD** (continued from previous page)

gonads, if present, should be removed due the risk of malignization.

Patients with CAIS need a particular approach, since later hormonal virilization is not possible. They have a completely female external phenotype with a short vagina and no internal female genital organs. They are raised as females and usually have a later diagnosis at adolescence with primary amenorrhoea. Laparoscopic removal of the gonads is the proposed procedure but the chosen timing of the orchiectomy varies in different series.<sup>8</sup>

**Ovotesticular DSD**

These very rare patients have the expression of ovarian and testicular tissue. Gender assignment becomes very difficult. If female gender is assigned, laparoscopic removal of testicular tissue, preserving the female gonadal portion can be tried. If male gender is assigned, laparoscopic removal of female gonadal tissue and the Müllerian structures (uterus and vaginal component of urogenital sinus) can be tried. Any retained testis should be placed in palpable position for surveillance.

**Sex chromosome DSD**

The major concern in this group is the presence of dysgenetic and streak gonads, strongly associated to malignant change (gonadoblastomas and/or an invasive germ cell tumor), especially when associated to chromosome Y or part of it. Laparoscopic removal of the gonads is the preferred approach. If male gender is assigned, laparoscopic removal of female gonadal tissue and the Müllerian structures are also performed in the same procedure.<sup>9</sup>

Despite the variability of the patients' presentations, the laparoscopic technique is very similar in almost all the procedures.

The patients had general anaesthesia with endotracheal intubation. A nasogastric tube and a bladder catheter are placed. The patient should be completely re-examined under anaesthesia, especially the external genitalia and perineal orifices. Careful palpation of the inguinal area looking for gonads and hernias is also important. The entire abdomen and the genital area are cleansed and prepared.

When combined genitoplasty was planned, the patient is placed in the semi-lithotomy position, for free perineal access, or otherwise supine. The video monitor, insufflator and light source were positioned near the feet of the patient. The surgical technique included the classical steps for laparoscopic surgery, i.e. peritoneal insufflation with a Veress needle inserted infraumbilically, or an open access with a Hasson trocar in small children. Usually a 5–10 mm umbilical trocar is introduced for initial laparoscopic evaluation. One or two additional 3–5 mm pelvic trocars are inserted under laparoscopic guidance in the iliac regions, usually halfway between the umbilicus and the anterior-superior iliac spines, for therapeutic procedures. Trendelenburg's position is useful to move away intestinal loops and get better pelvic exposure.

The gonadal structures were evaluated initially, and when necessary, the bowel retracted. In some cases when the gonads are not easily seen, the gonadal vessels may be identified and followed downwards. Most often, the gonads are identified near the inguinal region, eventually with normal testicular or ovarian appearance, but also with a dysplastic or tumoral aspect. In some cases the gonads are not clearly identified because of dysplasia, sometimes leading to confusion with ductal structures. Once identified, the gonads are resected, most often together with the ductal structures.

Müllerian derivatives usually extend between the gonads and the retrovesical space. In the midline behind the bladder lie the uterus and the vagina. In the presence of a normal testis in a patient with a male social sex, laparoscopic orchidopexy is the chosen procedure.

After laparoscopy, genitoplasty can also be performed, when needed.<sup>10</sup>

From 1994 to 2011 seventy two patients with DSD were submitted to laparoscopic procedures by our multidisciplinary group at the University of São Paulo. The overall results are remarkably encouraging. There was neither complication during surgery nor conversion to laparotomy. In most cases the identification of the gonads and Müllerian derivatives was easy and their removal, when indicated, straightforward. Complementary perineal resection of the inferior vaginal segment of the urogenital sinus was required in some cases. Genitoplasty, according to social sex, was usually performed during the same surgical procedure. Postoperative complications were very few and easily managed.

Important to mention is that we treated not only DSD children, but also many DSD adults. In our opinion, age of the patient does not interfere in the diagnostic work-up or therapy, except for the fact that older patients have already defined their social sex, and treatment must be adequate to the role of choice. Unfortunately, due to our social and geographical conditions, many of our patients only seek medical care as adults.

In conclusion, laparoscopy enables easy access to the pelvic structures, allowing an improved visualization and easy removal of unwanted intra abdominal gonads and ductal remnants in intersex patients with low morbidity. Compared to laparotomy, laparoscopy provides similar or better results with less postoperative pain and fewer incisional scars, which is very important in these patients who are

(continued on next page)

Table 1: Guidelines for the laparoscopic management of the gonads and Müllerian derivatives in intersex patients

Clinical Diagnosis	Social gender	Procedure
46, XX DSD	Male	Gonadectomy Resection of Müllerian structures
46, XY DSD	Female	Gonadectomy
	Male	Orchiopexy/Gonadectomy Resection of Müllerian structures
Ovotestis DSD	Female	Orchiopexy/Resection of ovotestis
	Male	Orchiopexy/Resection of ovotestis Resection of Müllerian structures
Gonadal Dysgenesis	Female	Gonadectomy (Chrom Y +)
	Male	Gonadectomy (Chrom Y +) Resection of Müllerian structures

**DSD** (continued from previous page)

very conscious of their body image. According to our experience, we understand that laparoscopy is the first choice for evaluation and handling of the internal genitals in intersex patients and that laparotomy has become obsolete in the treatment of these patients.

**References**

1. Hughes IA, Houk C, Ahmed SF, Lee PA; LWPEES Consensus Group; ESPE Consensus Group. Consensus statement on management of intersex disorders. *Arch Dis Child.* 2006 Jul;91(7):554-63. Epub 2006 Apr 19.
2. Hughes IA.: *The quiet revolution: Disorders of sex development.* *Best Pract Res Clin Endocrinol Metab.* 2010 Apr;24(2):159-62. Review.
3. Dénes FT, Mendonça BB, Arap S.: *Laparoscopic management of intersexual states.* *Urol Clin North Am.* 2001 Feb;28(1):31-42. Review.
4. Vidal I, Gorduza DB, Haraux E, Gay CL, Chatelain P, Nicolino M, Mure PY, Mouriquand P.: *Surgical options in disorders of sex development (dsd) with ambiguous genitalia.* *Best Pract Res Clin Endocrinol Metab.* 2010 Apr;24(2):311-24. Review.

5. Chavhan GB, Parra DA, Oudjhane K, Miller SF, Babyn PS, Pippi Salle FL.: *Imaging of ambiguous genitalia: classification and diagnostic approach.* *Radiographics.* 2008 Nov-Dec;28(7):1891-904.
6. Rangecroft L; British Association of Paediatric Surgeons Working Party on the Surgical Management of Children Born With Ambiguous Genitalia. *Surgical management of ambiguous genitalia.* *Arch Dis Child.* 2003 Sep;88(9):799-801.
7. Sircili MH, e Silva FA, Costa EM, Brito VN, Arnhold IJ, Dénes FT, Inacio M, de Mendonca BB.: *Long-term surgical outcome of masculinizing genitoplasty in large cohort of patients with disorders of sex development.* *J Urol.* 2010 Sep;184(3):1122-7. Epub 2010 Jul 21.
8. Mendonca BB, Domenice S, Arnhold IJ, Costa EM.: *46,XY disorders of sex development (DSD).* *Clin Endocrinol (Oxf).* 2009 Feb;70(2):173-87. Review.
9. Lambert SM, Vilain EJ, Kolon TF.: *A practical approach to ambiguous genitalia in the newborn period.* *Urol Clin North Am.* 2010 May;37(2):195-205.
10. Dénes FT, Cocuzza MA, Schneider-Monteiro ED, Silva FA, Costa EM, Mendonca BB, Arap S.: *The laparoscopic management of intersex patients: the preferred approach.* *BJU Int.* 2005 Apr;95(6):863-7.

## Laparoscopic Sigmoid Vaginoplasty

Maria Marcela Bailez, MD

Head of Surgical Department, J.P. Garrahan Children's Hospital, Buenos Aires Argentina  
Estela Susana Cuenca, MD, Pediatric Surgeon, J.P. Garrahan Children's Hospital

### Introduction: Applications, Strengths and Weaknesses of the Technique

There are a variety of conditions with total or partial absence of vagina in which a neo-vagina has to be created. If a vaginal orifice is present, the treatment of choice is passive or active elongation.<sup>1</sup>

When this technique fails either because of lack of motivation or in cases of a flat perineum, a surgical correction should be attempted. Surgical approach varies according to clinical and emotional condition of the affected adolescent and surgeon's experience.<sup>2</sup>

Techniques that have been used more frequently are the McIndoe operation and its modifications, and vaginoplasty using an amniotic allograft.<sup>3</sup> Amniotic allograft is used less frequently now because of fear of transmission of HIV. Both techniques are successful in 75 to 85% of the cases.<sup>4,5</sup> Other techniques described include Williams' operation (which uses vulvar skin), Johnson's operation (using skin from the back), Vecchietti's operation (laparoscopic elongation), use of buccal mucosa, or Pratt operation which uses sigmoid colon.<sup>6,7,8</sup> Even though the use of sigmoid colon is not frequently quoted in the gynecological literature, the good results obtained with this technique repairing complex malformations or those associated with absence of vagina such as a cloaca, or anorectal malformations with rectovulvar or rectovestibular fistula, which should be repaired in a single operation, encouraged us to optimize this technique for isolated vaginal replacement.<sup>9,10,11,12</sup> The use of sigmoid for vaginal replacement is a well-quoted operation in the pediatric urology literature.<sup>13</sup> With this technique a tubular vagina with natural lubrication is created, without need for the use of molds.

Two major advantages of this procedure are: there is no need for dilatation or use of some kind of a mold in the vagina, and the neovagina has natural lubrication.<sup>14</sup> One of its major disadvantages is the need for a laparotomy, implicating pain, nasogastric suction and discomfort. Since the advent of mechanical suturing, we have no longer used routine nasogastric suction. Our next goal has been the avoidance of laparotomy, so we started doing it completely laparoscopically in 1998. Providing its excellent visualization, access to pelvic structures and

less postoperative adhesion, laparoscopy has been an important tool for the treatment of uterovaginal anomalies. We have used it to define the anomalies, monitor endometriosis or a hysteroscopic procedure and resect abnormal Müllerian structures in the spectrum of congenital uterovaginal anomalies. Laparoscopy has not only been useful for the diagnosis and treatment of patients with isolated uterovaginal anomalies but also for the management of those with selected anorectal malformations (ARM) or disorders of sexual differentiation (DSD) with associated Müllerian anomalies.

In addition the undisputed advantage of endoscopic surgery in preventing adhesions makes it the procedure of choice for gynecological surgery. There is less tissue handling and fewer opportunities for foreign body contamination during laparoscopy. Nowadays many young females ask for it because they prefer to undergo a 2 or 3 hours long surgical procedure under general anesthesia to have their corporal squema [scheme] complete without any need of repeated and somehow painful elongations.

With the widespread culturing of vaginal epithelium it is likely that in the future an ideal vaginoplasty material will become available.

We started doing it in selected rare 46XY DSD patients with very little space between the urethra and rectum and then extended its use in others with Müllerian dysgenesis (Mayer Rokitansky syndrome). It is characterized by an absence of the vagina with or without uterine remnants. Associated renal and skeletal malformations are frequent, like renal agenesis, horseshoe kidney and cervical scoliosis, and diagnosis can be made earlier if a routine genital exam is indicated in these high-risk group. Most of the patients in this group are adolescents presenting with primary amenorrhea.<sup>15</sup> We only indicate this technique in patients mature enough to discuss and select from different options.

Occasionally we had the opportunity to do it earlier: pubertal patients with a functional Müllerian structure and a complete absent vagina or a 2 years old girl with an uterovaginal rhabdomyosarcoma requiring total vaginectomy who underwent a simultaneous laparoscopic vaginal replacement. We always rule out familial history of colonic polyposis or colonic cancer before using colon.

(continued on next page)

## Laparoscopic Sigmoid Vaginoplasty (continued from previous page)

### Evolution of Surgical Technique

In the 2000 we reported the first patient who underwent a laparoscopic sigmoid vaginal replacement and the results of its use later.<sup>16</sup> Our experience with the next 14 patients was published in 2004 and 2008.<sup>17,18</sup>

The initial operative technique is available in websurg ([www.websurg.com](http://www.websurg.com)). On that time, we used 4 ports: A 10mm one (umbilical), a 12 mm (right lower quadrant) and two 5 mm (left lower quadrant and hypogastric) (Fig 1). The lens was initially introduced through the umbilical port but later on moved to the right lower quadrant one in order to achieve better visualization of the vascularization of the sigmoid colon.

A segment of 15 cm of sigmoid colon was isolated using bipolar HFE, or the bipolar sealer (Ligasure™), and two linear endostaplers (Fig2 A/B/C). The sigmoid may be transilluminated with a 5mm lens inserted through the port in the left lower quadrant to facilitate vessels visualization.

Colo-colonic continuity was reestablished using a circular mechanical suturing device. The proximal end of the colon was exteriorized through the umbilicus, the proximal part of the circular stapling device inserted, and the colon returned to the abdominal cavity. The remaining part of the stapling device was inserted through the rectum. Both parts of the stapling device were assembled intraabdominally under

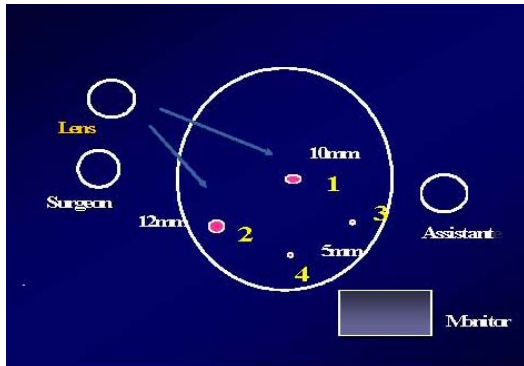


Fig 1: Operating Room Configuration

1. Umbilical Initial Lens port. Surgeon left hand port after the lens is inserted in port 2
2. Lens Port during vascular pedicle isolation (front vision). Endostappler port for sigmoid (neovagina) isolation
3. Assistant port for sigmoid traction and vascular transillumination
4. Surgeon Right hand port.

laparoscopic control (Fig 3), and the stapling device fired. Then a space was created between the urethra and rectum by perineal dissection but under laparoscopic verification.

The peritoneum near the Douglas' space was incised in order to allow the passage of a forceps from the perineum, which enabled the descent of the isolated bowel segment (Fig 4). The vaginoplasty was completed from the perineal side using 5/0 absorbable sutures avoiding a circular ending and rather opening the bowel ending widely to avoid stenosis.

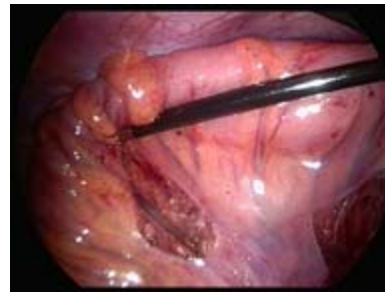


Figure 2A

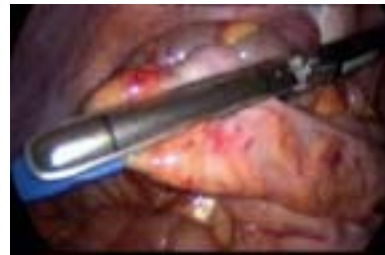

Figure 2B

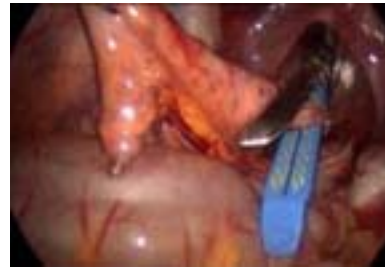

Figure 2C

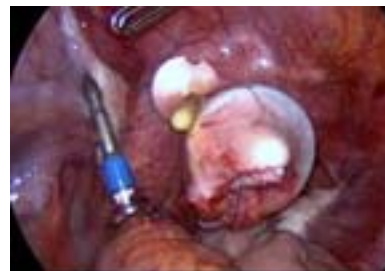

Figure 3

### Last Technical Modifications

We modified the original technique during the last year: 1) Reduce the port size 2) Use a different hemostatic device 3) Use the NOTES (Natural Orifice TransEndoscopic Surgery) concept.

1) We reduce the port sizes using a 4mm 30 degree lens in the umbilicus, two 3mm operative ports in each lower quadrant and one 5mm suprapubic port.

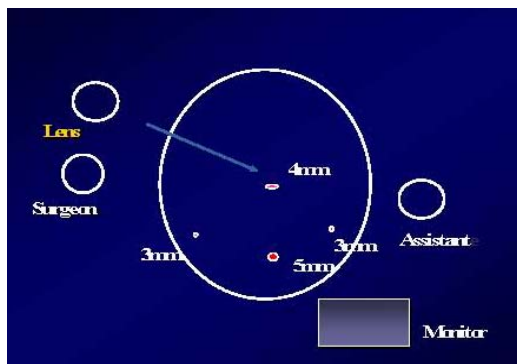
With the advent of HD cameras it is possible to have an excellent view of the pelvis with low diameter lens in a nearly adult pelvis. We still need a 5mm port for the use of the hemostatic device and we choose the suprapubic port for cosmetic and ergonomic reasons. The surgeon uses the 3mm right lower quadrant port for his left hand and the suprapubic 5mm port for his right one.

The assistant retracts the colon using traction and contraction maneuvers using the left 3mm port.

2) We started using a 5mm bipolar sealer with a monopolar cautery tip, all hand activated, avoiding changing instruments as much as possible (Fig 5)

3) After isolating vessels and creating the mesenteric windows of the selected piece of sigmoid as previously described, we

(continued on next page)



Modification the original technique: Reduced ports sizes.

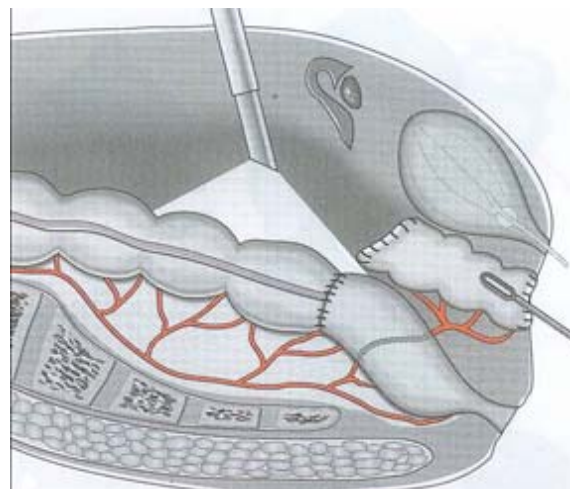


Figure 4

## Laparoscopic Sigmoid Vaginoplasty (continued from previous page)

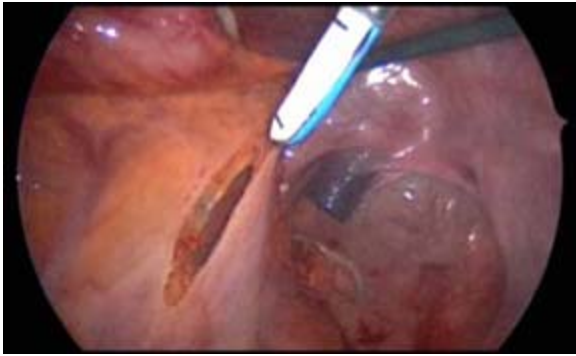


Figure 5

proceed to dissect space between the urethra and rectum, a 12mm port and the linear stapler sutures inserted through it.

The proximal transected colon is also exteriorized through this space to introduce the anvil of the circular stapler and reintroduced into the abdomen afterwards.

In this way we use the space created for the neovagina as a natural orifice to introduce a 12mm port and stapler (NOTES concept) achieving better cosmetic results.

### Results

Fifty-four patients were operated using a laparoscopic sigmoid vaginoplasty. Mean age was 16.3 years (range 15 – 32 y). Forty-nine had a Mayer-Rokitansky syndrome and five were “male pseudohermaphrodites”, three of them had complete androgen insensitivity and had been previously treated by laparoscopic bilateral orchidectomy. Four patients had a single pelvic kidney. One patient had an ARM previously operated through a sagittal-posterior approach with a colostomy. She underwent a simultaneous resection of a Müllerian functional remnant. One patient had a previously failed skin vaginoplasty and a laparotomy.

All patients were informed about different treatment modalities and chose for this procedure. Mean operative time was 150 min (range 100 min – 320 min).

There was one accidental opening of the bladder that was sutured laparoscopically. The urine catheter was left in for 3 days. We learned that a complete perineal dissection of the vesicorectal space is required before trying to open it from above. Two patients presented transient rectal bleeding. A right pelvic kidney made the procedure more difficult and required more “camera work”. In contrast, a left pelvic kidney exposed the sigmoidal vessels very well, which made the isolation of a sigmoid colon segment easier.

All patients were able to tolerate food 24 hours after the procedure and 50 patients were discharged 48 hours after the operation. Care needs to be taken with the technical changes to avoid descending the colocolonic anastomosis instead of the isolated bowel. Explanation may be that the proximal end of the colon exteriorized through the perineum has a sort of memory to go down again so it is advisable to double check every segment before opening the distal exteriorized end to create the neovagina.

Viability and patency of neovagina are excellent in 50 patients after a mean follow up of 46 months (range 6 -108m) and 40 patients are sexually active (Fig7). Two patients developed mucosal prolapse and 4 needed introital revisions. Excessive mucous secretion was not observed, except in 1 patient; it may be explained because the length of bowel used.

### Conclusions

To sum up, for us the main pros for using MIS sigmoid colon as neovagina are that there is one surgery, the neovagina has some natural lubricant, there is no need for dilatation and the well-described advantages of every MIS procedure.

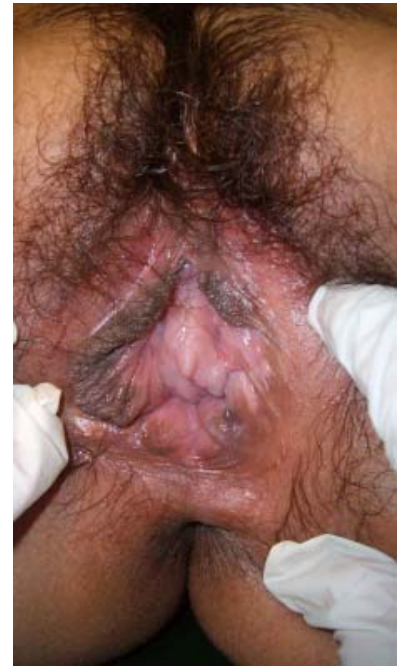

Figure 7

### References

- Ingram JM. The bicycle seat stool in the treatment of vaginal agenesis and stenosis :a preliminary report. *Am J Obstet Gynecol* 1981; 140:867- 869.
- Tjaden B L, Rock J. Uterovaginal Anomalies. In: Carpenter SE, Rock J (eds) *Pediatric and Adolescent Gynecology* 20. 1992 Raven Press, New York pp: 313-330.
- Mc Indoe A. The treatment of congenital absence and obliterate conditions of the vagina. *Br J Plast Surg*; 1950, 2: 254- 257.
- Rock J, Reeves L, Retto H, et al. Success following vaginal creation for mullerian agenesis. *Fertil Steril* 1983; 39(6):809.
- Strickland JL, Cameron WJ, Krantz KE, et al. Long-term satisfaction of adults undergoing Mc Indoe vaginoplasty as adolescents. *Adolesc Pediatr Gynecol* 1993; 6: 135-137.
- Muran D, Frederick R and Shell D : Modified Williams Vulvovaginoplasty: The role of tissue expanders. *Adolesc Pediatr Gynecol* 1992; 5: 81 -83.
- Samuelson M, Baker L. Autologous buccal mucosa vulvovaginoplasty for high urogenital sinus. *J Pediatr Urol* 2006; 2 (5): 486-488.
- Pratt JH. Vaginal atresia corrected by use of small and large bowel. *Clin Obstet Gynecol* 1972; 15: 639-649.
- Bailez M, Heinen F, Solana J. Absent vagina in patients with anorectal anomalies. *BJU* 1998; 81:76-76.
- Giovanni B, Zaffaroni G, Milena D et al :Proctoperineovaginohysterstomy and sigmoid colon pull-through for vaginal agenesis, hematocervicometra and vestibular anus. *Adolesc Pediatr Gynecol* 1993; 6:95 -98.
- Hendren H. Management of cloacal malformations. *Semin Pediatr Surg* 1997; 6 : 217-227.
- Peña A. Atlas of surgical management of anorectal malformations. New York. Springer Verlag 1990; p 19.
- Rock J A , Sclaff WD. The obstetrical consequences of uterovaginal anomalies. *Fertil Steril* 1985; 43 : 681 692.
- Novak F, Kos L, Plesko F. The advantages of the artificial vagina derived from sigmoid colon. *Acta Obstet Gynecol Scand* 1978; 57: 95 -97.
- Rock JA. The double uterus associated with an obstructed hemivagina and ipsilateral renal agenesis. *AmJ Obstet Gynecol* 1980; 138-339.
- Bailez MM, Scheri H, Dibenedetto V, et al. Laparoscopic vaginal replacement with sigmoid colon. *Pediatr Endosurg Innov Tech* 2000; 4:90.
- Bailez MM, Dibenedetto V, Elmo G and Korman L. Laparoscopic Sigmoid Vaginal Replacement. What we learned ? *Pediatric Endosurgery and Innovative Techniques* 2004; 8 4:295-301.
- Bailez M.M. Laparoscopy in Uterovaginal Anomalies. In: Bax K, Georgeson K, Rothenberg S, Valla J S, Yeung CK, editores. *Endoscopic Surgery in Infants and Children*. Berlin: Springer-Verlag; 2008.p.791-803.

Please visit the SPU website ([www.spuonline.org](http://www.spuonline.org)) to review

**PART I - APPLICATION OF MINIMALLY INVASIVE TECHNIQUES TO PEDIATRIC UROLOGY: DOING, TEACHING AND PUSHING ENVELOPES**

**Laparoscopic Pediatric Urology**

*Paul H. Noh, MD, FACS, FAAP*

**Robotic Surgery in Pediatric Urology: The First Decade**

*Craig A. Peters, MD, FAAP, FACS*

**Minimally Invasive Surgery: Surgical Training in Developing Countries**

*Maria M. Orellano, MD and Miguel A. Castellan, MD*

**Best Training Methods In Developed Countries**

*François Becmeur, MD, PhD, Isabelle Lacreuse, MD*

**Best Way of Training: How To Improve Learning Curve**

*Francisco Reed, MD and Soledad Celis, MD*

**Best Way of Training New Tricks For an Old Dog**

*Mr. Prasad Godbole FRCS,FRCS(Paed),FEAPU*

**PART II - UPDATE AND CONTROVERSIES IN LAPAROSCOPIC PAEDIATRIC UROLOGY - ORCHIOPEXY AND UPPER TRACT**

**Single-Stage Laparoscopic Orchidopexy**

*Lane S. Palmer, MD, FACS, FAAP*

**Laparoscopic Two-Stage Fowler-Stephens Procedure For Undescended Testis – A Personal Perspective**

*Francisca Yankovic, MD, Imran Mushtaq, MBChB, MD, FRCS (Glasg.), FRCS (Paed.)*

**Retroperitoneoscopic Nephro-Ureterectomies**

*Marc-David LeClair, MD, PhD, FEAPU, Alaa El-Ghoneimi, MD, PhD, FEAPU*

**Transperitoneal Laparoscopic Approach for Nephrectomy and Nephroureterectomy**

*Jason M. Phillips, MD, Duncan T. Wilcox, MD*

**Laparoscopic Approach For Kidney Tumors**

*Francisco Tibor Dénes, MD, Ricardo Jordão Duarte, MD*

**Laparoscopic Adrenalectomy In Children: Is It The Gold Standard?**

*Rodrigo Marcus Cunha Frati, MS, Carlo Camargo Passerotti, MD, PhD*

**Assisted Laparoscopic Surgery For Pyeloplasty**

*Simona Gerocarni Nappo, MD, FEAPU, Paolo Caione, MD, FEAPU*

**Pyeloplasty: Retroperitoneal Approach**

*Jeff Valla, PhD*

**Transperitoneal Laparoscopic Pyeloplasty: More Room, More Feasibility**

*Soledad Celis, MD, Pedro-José López, MD*